

XVII. *On the Blood-Vessels of Mustelus Antarcticus: a Contribution to the Morphology of the Vascular System in the Vertebrata.*

By T. JEFFERY PARKER, *B.Sc. Lond., C.M.Z.S., Professor of Biology in the University of Otago.*

Communicated by Professor M. FOSTER, M.D., Sec. R.S.

Received June 4,—Read June 10, 1886.

[PLATES 34—37.]

CONTENTS.

	PAGE.
Introductory	685
I. THE ARTERIES.	
1. The ventral aorta and afferent branchial arteries	686
2. The efferent branchial arteries, epibranchial arteries, and dorsal aorta ..	687
3. The peripheral arteries	692
A. Arising from the efferent branchial arteries	693
B. Arising from the dorsal aorta	696
II. THE VEINS	702
A. System of the sub-intestinal vein	703
i. Renal portal section	703
ii. Hepatic portal section	705
B. System of the cardinal veins	710
C. " " lateral "	716
D. " " coronary "	720
E. " " cutaneous "	720
General considerations	721
Methods of investigation	722
Bibliography	725
Description of plates	726

THE present inquiry was undertaken with a view of settling, if possible, one or two doubtful points in our knowledge of the vascular system of Fishes, and of giving, in an accessible form, a fairly complete account of the blood-vessels of a typical Selachian, since, as far as I am aware, this has not yet been done. The arteries and veins of the Skate are figured, for the most part very accurately, by MONRO (16)*; the arteries of

* The figures between brackets refer to the bibliographical list at the end of the paper (p. 725).

Raja and *Torpedo* are described and figured in detail by HYRTL (11), and there are good general accounts of the vascular system in both orders of *Plagiostomi* in the works of MÜLLER (17), STANNIUS (25), and MILNE EDWARDS (14). By all these authors, however, several points of considerable importance are either missed or but slightly referred to, while others are more or less inaccurately described.

In all the more modern text-books of comparative anatomy to which I have had access the vascular system of Fishes is very meagrely treated, the manuals of OWEN (19), HUXLEY (10), CLAUS (4), GEGENBAUR (7), ROLLESTON (24), MACALISTER (13), GÜNTHER (8), and WIEDERSHEIM (26), adding little or nothing to the excellent though brief account in STANNIUS'S handbook just referred to. Indeed, the only general work I have seen which gives any important information not to be found in STANNIUS is MILNE EDWARDS'S 'Leçons,' in which the description of the vascular system, and especially of the arteries of Fishes, is full, and, like everything else in that invaluable book, admirably clear.

Great attention has been directed of late years to the Selachians, since it is evident that they are the nearest existing representatives of the ancestral stock of the higher or gnathostomatous Vertebrata. Their skeleton, muscles, nervous system, urinogenital organs, and general embryology have all been made the subjects of special study within the last few years, but, as far as I am aware, the only important contributions to our knowledge of their vascular system, since the publication of MILNE EDWARDS'S third volume, are JOURDAIN'S discovery of their renal-portal system (12) and BALFOUR'S researches on the development of their veins (1 and 2).

I. THE ARTERIES.

1. *The Ventral Aorta and Afferent Branchial Arteries.*

a. Ventral aorta.

Branchial artery, MONRO (16), OWEN (19), GEGENBAUR (7).

Arteria branchialis, MÜLLER (17).

Artère branchiale, MILNE EDWARDS (14).

Kiemenarterienstamm, STANNIUS (25).

Cardiac aorta, HUXLEY (10).

Aorta, aorta ascendens, cardiac aorta, CLAUS (4).

Ventral aorta, branchial artery, BALFOUR (2).

Hauptstamm der Kiemenarterie, WIEDERSHEIM (26).

b. Afferent branchial arteries.

Branches of branchial artery, MONRO (16).

Kiemenarterien, HYRTL (11).

Artères branchiales propres, MILNE EDWARDS (14).

Branchial arteries, CLAUS (4).

The ventral aorta (Plate 34, figs. 1 and 2; Plate 37, fig. 18; *V. Ao.*) of *Mustelus antarcticus* presents no points of special interest. Immediately after its origin from the short conus arteriosus (*C. Art.*) it gives off on each side a short outwardly-directed trunk which almost immediately divides into the afferent arteries of the fourth and fifth gills (*Af. br. A. 4* and *Af. br. A. 5*), that is, those borne by the third and fourth branchial arches respectively. Passing forwards, the ventral aorta gives off a single trunk on either side to the third gill (*Af. br. A. 3*), and, at its anterior termination, divides into two vessels, each of which passes directly outwards, soon dividing into the first and second afferent branchial arteries (*Af. br. A. 1* and *Af. br. A. 2*). Of these the former (*Af. br. A. 1*) is distributed to the hyoidean hemibranch,* the latter (*Af. br. A. 2*) to the gill of the first branchial arch or first complete gill.

The precise position of the afferent artery with regard to the various constituents of the gill is best seen in transverse section and will be described immediately (p. 688).

2. The Efferent Branchial Arteries, Epibranchial Arteries, and Dorsal Aorta.

a. Efferent Branchial Arteries.

Branchial Veins, MONRO (16), OWEN (19), HUXLEY (10), GEGENBAUR (7),
ROLLESTON (24), MACALISTER (13), BALFOUR (2).

Kiemenvenen, HYRTL (11), STANNIUS (25).

Venæ branchiales, MÜLLER (17).

Artères epibranchiales (in part), MILNE EDWARDS (14).

Epibranchial arteries, branchial veins, CLAUS (4).

b. Epibranchial Arteries.

Aortenwurzeln, HYRTL (11), DOHRN (5).

Radices aortæ, WIEDERSHEIM (26).

Venæ branchiales communes, MÜLLER (17).

Artères epibranchiales (in part), MILNE EDWARDS (14).

c. Dorsal Aorta.

Trunk of descending aorta, MONRO (16).

Aorta descendens, MÜLLER (17).

Aorta, HYRTL (11), STANNIUS (25), OWEN (19).

Aorta abdominalis, WIEDERSHEIM (26).

Aorta dorsale, MILNE EDWARDS (14).

Dorsal aorta, HUXLEY (10).

Dorsal aorta, aorta descendens, CLAUS (4).

As usual in Plagiostomes, which in this, as in many other points of structure, differ from all other amphirrhinous fishes, there is an efferent branchial artery for each

* I have adopted (in 23) this very convenient word as the equivalent of MILNE EDWARDS'S "demi-branchie." It means the whole set of gill-filaments on one side of a gill pouch in a Cyclostome or an Elasmobranch. A complete gill, composed of two hemibranchs, may be appropriately termed a *holobranch*.

hemibranch or half-gill, and consequently nine such arteries in all (Plates 34 and 35, figs. 1, 2, and 6, *Ef. br. A.* 1-9), one for the hyoidean hemibranch (*Ef. br. A.* 1) and two for each of the holobranchs or complete gills borne by the first four branchial arches. The anterior artery of each holobranch (*Ef. br. A.* 2, 4, 6, and 8) is markedly larger than the posterior.

These vessels are usually, but very incorrectly, called *branchial veins*. It would be quite as justifiable to speak of the *portal artery* as to call these obviously arterial vessels veins; a capillary system may be interposed in the course either of an artery or of a vein, but this does not make the efferent trunk in the one case a vein, nor the afferent trunk in the other case an artery.

The relations of the afferent and efferent branchial arteries to one another and to the other structures of the gill are well seen in transverse section. Fig. 5 represents a section of the second holobranch taken through the dorsal end of the cerato-branchial. It shows the crescentic transverse section of the cerato-branchial (*C. br.*) and the reniform section of the extra-branchial (*Ex. br.*); one of the cartilaginous branchial rays (*Br. r.*) is cut longitudinally, as also are two branchial filaments (*Br. fil.*) belonging to the anterior and posterior hemibranchs respectively. A muscle which flexes the epi- upon the cerato-branchial, and may be called the *M. epi-cerato-branchialis* (*M. ep. c. br.*), is shown in transverse section, and the great radiating muscle of the gill (*M. rad.*) in longitudinal section. It is seen that the afferent artery (*Af. br. A.* 3) lies between the radiating muscle and the branchial ray, and immediately external to the branchial arch; while of the two afferent vessels, one (*Ef. br. A.* 4) is situated a short distance anterior to the radiating muscle, the other (*Ef. br. A.* 5) immediately posterior to the branchial ray. The two branches of the vagus (*nv*¹, *nv*²) are situated immediately cephalad of the radiating muscle and caudad of the branchial ray respectively.

The radiating muscle may be taken as indicating the position of the head cavity in the embryonic gill-arch, so that, as DOHRN has shown (5), the afferent and the posterior efferent arteries lie caudad, the anterior efferent artery cephalad of the head cavity.

The efferent branchial arteries unite with one another in a characteristic manner (Plate 35, fig. 6), the arteries of the anterior and posterior hemibranchs of each gill-pouch—not of each gill—*anastomosing* both dorsally and ventrally so as to form a complete loop. Thus the artery of the hyoidean hemibranch (*Ef. br. A.* 1) unites with that of the anterior hemibranch of the first branchial arch (*Ef. br. A.* 2); the artery of the posterior hemibranch of the first branchial arch (*Ef. br. A.* 3) with that of the anterior hemibranch of the second arch (*Ef. br. A.* 4), and so on. Four arterial loops are thus formed on each side, the ventral ends of which are united by a longitudinal commissure (*com.* 1).

Further, the two arteries of each holobranch are placed in communication at about the middle of their length by two short transverse anastomoses (*com.* 2);

it is through these that the ninth or last efferent artery (*Ef. br. A. 9*) pours its blood into the eighth; it forms, of course, no loop, since the fifth branchial arch is gill-less.

From the dorsal end of each arterial loop an *epibranchial artery** (*Epbr. A. 1-4*) is continued backwards and inwards: by uniting with one another successively in pairs these four trunks form the *dorsal aorta* (*D. Ao.*). As seen in fig. 6 the first pair (*Epbr. A. 1*) unite in the middle line and form a short median trunk; this is joined by the second pair, a thicker trunk being the result; then the third pair join in like manner, and finally the fourth (*Epbr. A. 4*).

The regular manner in which the epibranchials of *Mustelus* unite is worthy of notice as a clearly primitive arrangement. In the Rays (23, fig. 20), *Holocephali* (Plate 36, fig. 17), and *Teleostei* (23, fig. 32), two or more of the epibranchials of the same side unite with one another before joining with those of the opposite side.

In the embryo the aortic arches are continued directly from the ventral to the dorsal aorta. In *Holocephali* (Plate 36, fig. 17) and *Teleostei* there is only one efferent artery to each gill, corresponding to the anterior of the two efferent arteries in the plagiostome holobranch. This is very evident in *Callorhynchus*, in which the single efferent artery of each gill is always cephalad of the corresponding afferent trunk. These facts tend to confirm the opinion to which one is led by the simple inspection of the parts in the adult *Mustelus* (compare figs. 6 and 17); namely that the anterior efferent artery of each holobranch (*Ef. br. A. 2, 4, 6, and 8*) is to be looked upon as its primary revehent trunk and as strictly continuous with the corresponding epibranchial artery, the posterior efferent artery being a secondary vessel which debouches not into the primary trunk of its own, but into that of the next following gill.

The foregoing paragraph was originally written fully a year ago, before I had seen DOHRN's paper on the "Development of the Gill-Arches" referred to above (5). It is satisfactory to find that the views just enunciated are largely confirmed by embryology. DOHRN shows that the aortic arch in *Pristiurus* is at first single, lying caudad of the head cavity. When the gill filaments are developed, accessory blood-currents (*Nebenströme*) are set up, and give rise first to the posterior and then to the anterior efferent artery; both of these open at first into the dorsal region of the aortic arch, which afterwards becomes the epibranchial artery. Gradually the afferent trunk, formed from the ventral region of the original aortic arch, loses its connexion with the dorsal portion, so that afferent and efferent blood-streams, communicating only by capillaries, are now definitely established. Then, as development goes on, the anterior efferent artery increases at the expense of the posterior; much of the blood from the

* MILNE EDWARDS uses this word so as to include the corresponding efferent branchial arteries, but I think there can hardly be two opinions as to the convenience of restricting it to that portion of the efferent series of vessels lying dorsad of the gill.

latter is poured into the anterior trunk by the transverse commissures (*com.* 2), and, finally, the posterior efferent artery loses altogether its connexion with the aortic arch of its own branchiomere, and acquires a secondary one with the succeeding arch.

From the above considerations one is led to look upon the connexion of the first (hyoidean) efferent artery (*Ef. br. A.* 1) with the first epibranchial artery (*Epbr. A.* 1) as a secondary one, and it then becomes a matter of considerable interest to find in *Mustelus antarcticus* distinct remains of the dorsal portion of the hyoidean aortic arch, and of its connexion with the dorsal aorta.

From the dorsal end of the first efferent branchial artery arises a large vessel, the *posterior carotid artery* (*Post. car. A.*). This trunk passes forwards and inwards, ventrad of the proximal end of the hyomandibular, to the ventral surface of the auditory capsule, and then through a foramen in the skull floor to the orbit. Its further course will be described hereafter (p. 695), the point of interest for the present purpose is that shortly before entering the foramen just mentioned—at the point *x* in fig. 6—it gives off a very slender vessel (*y*), which passes backwards and inwards along the ventral aspect of the skull and vertebral column, and joins with its fellow of the opposite side to form a delicate longitudinal median trunk (*z*), which is continued backwards to the junction of the first pair of epibranchial arteries.

I think there can be no doubt that the posterior carotid artery, from its origin to the point *x*, together with its backward continuation *y*, represents the dorsal portion of the hyoidean aortic arch, or *hyoidean epibranchial artery*, the altered direction of the vessels being accounted for by the changed position of the hyoid arch.

The median trunk *z* is, as obviously, the actual anterior portion, or what may be called the inter-hyoidean section, of the dorsal aorta. It has clearly nothing whatever to do with the *arteria vertebralis impar* of Myxinoids (17) which it resembles at first sight, since the latter is a secondary forward prolongation of the aorta altogether cephalad of the gills. As this anterior portion of the dorsal aorta undergoes complete atrophy—if indeed it ever exists—in the Rays as well as in *Holocephali*, it is a matter of some interest to find it persisting in a typical Selachian, and one is led to inquire whether it is actually absent in those forms the arteries of which have been described, or whether it has hitherto been overlooked. I can only say that I have failed to find any mention of it.

The course of the mandibular aortic arch is by no means so clear and can only be decided by a detailed study of development. From about the middle of the first efferent branchial artery is given off the *pseudobranchial artery* (fig. 6, *Psbr. A.*), which passes forwards external to the articulation of the hyomandibular and epiphyal, and then extends forwards, upwards, and inwards to the spiracular pseudobranch (*Psbr.*), the rudiment of the mandibular gill of the embryo. The blood is collected from this organ by the *anterior carotid artery* (*Ant. car. A.*) which is continued inwards and forwards to the orbit, passes through a foramen in the side wall of the skull, and becomes the cerebral artery (*Cereb. A.*, *vide infra*, p. 694): while

imbedded in the perichondrial lining of the cranial cavity, it sends off a branch (*w*) which passes inwards and backwards, crossing its fellow of the opposite side in the thickened perichondrium of the pituitary space, and finally anastomosing with the posterior carotid of the opposite side.

From the ventral end of the first efferent branchial artery springs the *mandibular artery* (figs. 2, 6, and 10, *Mandib. A.*), which extends upwards along the outer face of the hyoid arch and just internal to the mandible, thus running parallel to the efferent branchial arteries. Distally it breaks up into several branches at about the level of the pseudobranchial artery (fig. 10). In *Callorhynchus* the evidently homologous vessel (Plate 36, fig. 17, *Mandib. A.*) anastomoses with the proximal end of the anterior carotid—which, in the absence of a pseudobranchia, springs directly from the first efferent branchial artery—and appears from its position and relations to represent the mandibular aortic arch.

From the analogy of *Callorhynchus* it would seem, therefore, that the mandibular artery is to be looked upon as a part of the original mandibular aortic arch, the rest of the ventral portion of which, represented by the pseudobranchial artery, has acquired a secondary connexion, comparable to the transverse commissures (*com.* 2), with the first efferent branchial artery. Whether the anterior carotid, together with the anastomotic trunk *w*, has anything to do with the original connexion of the mandibular aortic arch with the dorsal aorta (*mandibular epibranchial artery*) it is of course impossible to decide from anatomical evidence alone.

The following table shows what I conceive to be the relation of the arteries of the adult to the embryonic aortic arches :—

IN THE EMBRYO.	IN THE ADULT.	
	Dorsal Section.	Ventral Section.
1st Aortic arch (mandibular) . .	Commissure <i>w</i> (?), anterior carotid artery.	Pseudobranchial artery. Mandibular artery.
2nd Aortic arch (hyoidean) . . .	Vessel <i>y</i> ; posterior carotid from origin to <i>x</i> .	1st afferent branchial artery. 1st efferent branchial artery.
3rd Aortic arch (1st branchial) . .	1st epibranchial artery . . .	2nd efferent branchial artery. 2nd afferent branchial artery. 3rd efferent branchial artery.
4th Aortic arch (2nd branchial) . .	2nd epibranchial artery . . .	4th efferent branchial artery. 3rd afferent branchial artery. 5th efferent branchial artery.
5th Aortic arch (3rd branchial) . .	3rd epibranchial artery . . .	6th efferent branchial artery. 4th afferent branchial artery. 7th efferent branchial artery.
6th Aortic arch (4th branchial) . .	4th epibranchial artery . . .	8th efferent branchial artery. 5th afferent branchial artery. 9th efferent branchial artery.

3. *The Peripheral Arteries.*

The peripheral arteries of *Mustelus* may be classified as follows :—

- A. Arising from the efferent branchial arteries.
 - 1. The pseudobranchial and anterior carotid arteries.
 - a. The ophthalmic arteries.
 - b. The cerebral arteries.
 - a. The anterior cerebral arteries.
 - β. The posterior cerebral arteries.
 - γ. The myelonal artery.
 - 2. The posterior carotid arteries.
 - a. The orbital arteries.
 - b. The buccal arteries.
 - c. The maxillo-nasal arteries.
 - d. The rostral arteries.
 - 3. The mandibular arteries.
 - a. The sub-mental arteries.
 - b. The nutrient hyoidean arteries.
- B. Arising from the dorsal aorta.
 - 4. The subclavian arteries.
 - a. The hypobranchial arteries.
 - a. The anterior lateral arteries.
 - β. The coronary arteries.
 - γ. The nutrient branchial arteries.
 - δ. The pericardial artery.
 - b. The brachial arteries.
 - 5. The coeliaco-mesenteric artery.
 - a. The coeliac artery.
 - a. The anterior gastric artery.
 - β. The right hepatic artery.
 - γ. The left hepatic and pyloric arteries.
 - δ. The ventral gastric artery.
 - b. The anterior mesenteric artery.
 - a. The ventral intestinal artery.
 - β. The intra-intestinal artery.
 - 6. The anterior spermatico-mesenteric artery.
 - a. The anterior spermatic artery.
 - b. The dorsal intestinal artery.
 - 7. The lieno-gastric artery.
 - a. The pancreatic arteries.
 - b. The dorsal gastric arteries.
 - c. The splenic artery.

8. The oviducal arteries (in the female).
9. The posterior spermatico-mesenteric artery.
 - a. The posterior spermatic arteries.
 - b. The posterior mesenteric artery.
10. The renal arteries.
11. The dorso-lumbar (segmental) arteries.
12. The iliac arteries.
 - a. The femoral arteries.
 - b. The posterior lateral arteries.
13. The caudal artery.

A. *Arteries arising from the Efferent Branchial Arteries.*

(1.) *The pseudobranchial and anterior carotid arteries.*

a. The pseudobranchial artery.

Arterienstamm der Spritzloch-Nebenkieme, MÜLLER (17).

Abführendes Gefäß der Spritzlochkieme, HYRTL (11).

b. The anterior carotid artery.

Carotis anterior v. Carotis interna anterior, MÜLLER (17).

Carotis anterior, STANNIUS (25).

Carotide interne, MILNE EDWARDS (14).

Zuführendes Gefäß der Spritzlochkieme, HYRTL (11).

The course of these vessels has already been briefly described (p. 690). They are considered together because, although one is the afferent and the other the efferent trunk of the pseudobranch, they are practically continuous even in forms like *Mustelus* and *Raja*, in which the pseudobranch is present, while in those species—e.g., *Callorhynchus* (fig. 17)—in which the mandibular gill completely disappears, they form a single vessel to which the name *anterior carotid* is applied.

The application of the name "carotid" to the cephalic arteries of fishes must of course be taken to imply nothing more than a general correspondence with the similarly-named vessels in the higher Vertebrata. In Sauropsida and Mammalia the external carotid is formed from the ventral ends, the internal carotid from the dorsal ends of the aortic arches, the former supplying the head generally, the latter the brain and eye. In Plagiostomes the artery here called posterior carotid is, from its mode of origin, better entitled to the name "internal" carotid than any other vessel, and the mandibular artery to the name "external" carotid. As regards their distribution, however, it will be seen that these two arteries jointly perform the function of external carotid, while that of internal carotid is assigned to the artery now under consideration, the "anterior" carotid of MÜLLER.

These considerations make it desirable to drop the names "internal" and "external"

carotids, for the head arteries of fishes, altogether, and to follow MÜLLER in the use of the terms "anterior" and "posterior" carotid; at least until the embryology of the vessels is thoroughly made out in a large number of forms. At present any attempt to introduce a systematic nomenclature applicable to the whole of the Vertebrata could, it appears to me, only result in failure.

The pseudobranchial artery gives off no branches until it ramifies in the pseudobranch (Plate 35, figs. 6 and 10, *Psbr. A.*), from which the blood is collected by the anterior carotid artery (*Ant. car. A.*). This vessel passes inwards and forwards along the floor of the orbit, crossing ventrad of the posterior carotid (*Post. car. A.*). It sends off a small *ophthalmic artery* (*Ophth. A.*) to the eye, and then almost immediately enters the carotid foramen, an aperture in the skull wall about 5 mm. caudad of the optic foramen. Having entered the carotid foramen it passes obliquely inwards and forwards (fig. 6) through the thick perichondrial lining of the skull, is joined by the anastomotic branch *w* from the posterior carotid of the opposite side, and emerges into the cranial cavity as the *cerebral artery*.

The main *cerebral artery* (Plate 35, figs. 6 and 8, *Cereb. A.*) is a short trunk; it divides almost immediately, opposite the mesencephalon, into an anterior and a posterior cerebral.

The *anterior cerebral artery* (*Ant. cereb. A.*) passes forwards along the outer and ventral side of the prosencephalon, to which it sends a considerable branch, and finally breaks up into a brush-work of small arteries on the ventral surface of the olfactory lobe.

The *posterior cerebral artery* (*arteria profunda cerebri*, HYRTL, 11) gives branches to the diencephalon, mesencephalon, and cerebellum (*Post. cereb. A.*), and, passing to the ventral face of the medulla oblongata, unites with its fellow in the middle line, forming the median *myelonal artery* (*arteria spinalis inferior*, HYRTL, 11), which (*Myel. A.*) is continued along the ventral face of the spinal cord.

According to HYRTL (11) the blood, in *Raja* and *Torpedo*, reaches the cerebral artery, not, as described above, by the anterior carotid, but by the anastomotic branch *w*, which he calls the internal carotid (*vide infra*, p. 695). Part of the blood from this trunk is then taken by the anterior carotid (zuführendes Gefäss der Spritzlochkieme) to the pseudobranch, and thence by the pseudobranchial artery (abführendes Gefäss der Spritzlochkieme) to the first efferent branchial artery. So that, according to HYRTL, the anterior carotid is the afferent, the pseudobranchial artery the efferent trunk of the pseudobranch.

It seems to me that the relative sizes of the vessels sufficiently disprove this theory as far as *Mustelus* is concerned, the anterior carotid being a comparatively large vessel, many times larger than the anastomotic branch *w*, which is supposed to supply both it and the cerebral artery. In *Callorhynchus*, again, in which the anastomotic branch *w* is absent, the anterior carotid (Plate 36, fig. 17, *Ant. car. A.*) obviously becomes the cerebral (or more accurately cerebro-rostral) artery. So that I can see no reason for

supposing the embryonic blood-current to undergo the reversal which is pre-supposed by HYRTL'S view of the circulation through the pseudobranch.

(2.) *The posterior carotid artery.*

Carotis posterior v. *Carotis interna posterior*, MÜLLER (17).

Carotis posterior, STANNIUS (25).

Carotide interne postérieure, MILNE EDWARDS (14).

Carotis communis plus *Carotis externa*, HYRTL (11).

The course of the posterior carotid has already been partly described (p. 690). From its origin from the first efferent branchial artery it passes forwards and inwards (Plate 35, fig. 6, *Post. car. A.*) along the ventral face of the hyomandibular and auditory capsule, and enters the orbit through a foramen in its cartilaginous floor. The anastomotic trunk *w*, already referred to (*Carotis interna*, HYRTL), is given off just before entering this foramen; it passes inwards and slightly forwards along a groove on the skull floor. The groove soon becomes a canal through which the vessel in question reaches the pituitary space, where, imbedded in the thickened perichondrium, it crosses its fellow of the opposite side and unites with the anterior carotid of the opposite side, as already described (p. 694). The anastomotic trunk from the left posterior carotid passes ventrad of that from the right: HYRTL found exactly the opposite arrangement in *Raja clavata*.

In HYRTL'S paper (11) the posterior carotid, from its origin to the point of junction of the trunk *w*, is called the "common" carotid: the remainder of the artery is the "external" carotid, and the anastomotic branch *w*, the "internal" carotid. I have adopted these names in my "Zootomy" (23), but have now come to the conclusion, as stated above (p. 693), that it is advisable to discontinue their use. That they were ever employed is a striking instance of the danger of basing a nomenclature on the study of specialized forms.

Immediately after entering the orbit the posterior carotid gives off the *orbital artery* (Plate 35, figs. 6, 10, and 11, *Orbit. A.*). This sends off twigs to the posterior wall of the orbit, and then divides into two branches, a dorsal which supplies the superior rectus, superior oblique and inferior oblique muscles, and a ventral which supplies the internal and external recti. The inferior rectus apparently receives its blood supply from a special branch of the posterior carotid.

The posterior carotid then passes obliquely forwards and outwards, emerging from the orbit at its antero-ventral corner (fig. 10); it then gives off a large *buccal artery* to the M. adductor mandibulæ, and almost immediately divides into two trunks, the *maxillo-nasal artery* which passes forwards and downwards along the anterior edge of the upper jaw (pterygo-quadrato cartilage), and a *rostral artery* (*Rost. A.*) which goes at first forwards, upwards, and inwards, then forwards and inwards along the outer border of the lateral (paired) rostral cartilage.

3. *The mandibular artery.*

This (Plate 34, figs. 1 and 2, and Plate 35, figs. 6 and 10, *Mandib. A.*) is a considerable vessel springing from the ventral end of the first afferent branchial artery. It passes at first forwards, then outwards, upwards, and slightly backwards along the outer face of the hyoid arch, and just within the ventral border of the mandible. Close to its origin it sends off several small vessels (fig. 2, *Cor. mand.*) to the coraco-mandibularis muscle, and then a large branch, the *sub-mental artery* (*S. ment. A.*), which goes along the inner face of the mandible to the symphysis, also supplying the *M. coraco-mandibularis*. Distad of the origin of this latter vessel the mandibular artery gives off small branches at the angle of the mouth (*Add. mand.*) to the *M. adductor mandibulæ*, and nutrient arteries to the hyoidean hemibranch (*Nu. hy. A.*), and finally breaks up into a number of small twigs, which pass, for the most part, external to the pseudobranchial artery and supply the anterior part of the *M. constrictor superficialis*.*

B. *Arteries arising from the dorsal aorta.*

4. *The subclavian artery.*

Arteria subclavia, HYRTL (11).

Artère claviculaire, MILNE EDWARDS (14).

The subclavian arteries (Plate 34, figs. 1 and 2, and Plate 35, fig. 6, *Subcl. A.*) are comparatively small vessels, arising one on each side from the dorsal aorta immediately cephalad of the junction with it of the fourth pair of epibranchial arteries. Each subclavian passes outwards with a slight backward inclination, and, at about the junction of the cardinal with the precaval sinus (*vide infra*, pp. 728 and 729, figs. 1 and 2, *Card. S.*, *Pr. cav. S.*) turns forwards and downwards, and divides into two arteries, the brachial and the hypobranchial.

The origin of the subclavians from the dorsal aorta is worthy of notice, since in the higher Vertebrata the corresponding vessels always arise from an aortic arch.

The brachial artery

(*Brach. A.*) passes at first slightly forwards and downwards, then outwards through a foramen in the shoulder girdle, situated at about the level of the mesopterygium, to the pectoral fin, which it supplies.

* In the nomenclature of the muscles I follow VETTER, "Untersuchungen zur vergleichenden Anatomie der Kiemen- und Kiefermusculatur der Fische," 'Jenaische Zeitschrift,' vol. 8, 1874, p. 405.

The hypobranchial artery.

Figured, but not named, by MONRO (16).

Ventrale Verlängerungen der Venen des zweiten Kiemensackes (in *Raja*), HYRTL (11).

Grosse branche anastomotique, &c., MILNE EDWARDS (14).

Hypobranchial arteries, PARKER (23).

This remarkable system of arteries, forming an anastomosis between the efferent branchial and the subclavian arteries, was, as far as I am aware, first described by MONRO in the skate, and was afterwards more accurately figured in the same type by HYRTL. I have seen no account of any such vessels in Selachians; both MÜLLER and MILNE EDWARDS write as if they were confined to the Batoidei, and no mention of them is made in any of the text-books I have had the opportunity of consulting.

After separating from the brachial, the hypobranchial artery (Plate 34, fig. 2, *Hypbr. A.*) gives off a branch to the lateral body muscles, and then passes forwards and inwards through the ventral wall of the pericardial cavity, finally uniting with its fellow of the opposite side at about the level of the junction of the ventricle with the conus arteriosus. About midway between this junction and its origin from the subclavian each hypobranchial sends off a small *anterior lateral* artery (figs. 1 and 2, *Ant. lat. A.*), which accompanies the lateral vein and helps to supply the anterior body muscles.

The median trunk formed by the union of the paired hypobranchial arteries passes forwards and upwards amongst the muscles of the throat until it reaches the ventral aorta about 2 cm. cephalad of its origin from the conus arteriosus; it then breaks up (fig. 2) into a simple plexus, which is united by two pairs of commissural trunks with the longitudinal vessels (*com. 1*) uniting the ventral ends of the efferent branchial arteries. The anterior of these (*com. 3*) arises between the fourth and fifth efferent arteries and joins the median hypobranchial immediately ventrad of the origin of the third afferent branchial artery from the ventral aorta. The posterior commissure (*com. 4*) arises between the sixth and seventh efferent arteries and joins the hypobranchial at the level of the origin of the fourth and fifth afferent arteries. Cephalad of the anterior of these commissural trunks the median hypobranchial artery is continued forwards as a slender vessel, which, at the level of the anterior end of the ventral aorta, breaks up into a number of branches distributed to the *M. coracomandibularis*.

The coronary arteries

(Plate 34, fig. 2, *Cor. A.*) are two in number, and arise from the azygos hypobranchial artery close to the posterior pair of commissures (*com. 4*) from the efferent branchial arteries. The two coronaries pass backwards along the ventral face of the conus arteriosus, the right soon dividing into two, and branch out over the ventricle,

I have found no trace of a posterior coronary artery such as exists in the skate (11 and 23).

The nutrient branchial arteries.

Bronchialarterien, MÜLLER (17).

The hyoidean hemibranch, as stated above (p. 696), is supplied by several twigs of the mandibular artery. The first holobranch, or complete gill, receives its nutrient artery (*Nu. br. A. 1*) from the longitudinal commissure between the second and third efferent branchial arteries. The nutrient artery of the second holobranch (*Nu. br. A. 2*) arises from the azygos hypobranchial close to its junction with the anterior pair of commissures (*com. 3*) from the efferent branchial arteries; that of the third complete gill (*Nu. br. A. 3*) springs from the azygos hypobranchial near its junction with the posterior pair of commissures (*com. 4*).

The nutrient artery of each holobranch passes along the anterior border of the corresponding extra-branchial cartilage. There is a good deal of variation in the precise mode of origin of these vessels.

The pericardial artery

(Plate 34, fig. 2, *Pcard. A.*) is given off from the left posterior anastomotic trunk (*com. 4*) between the median hypobranchial and the efferent branchial arteries. It passes backwards and at the same time medianwards in the dorsal wall of the pericardial cavity, soon dividing into right and left branches.

5. *The coeliaco-mesenteric artery.*

Arteria coeliaco-mesenterica (in *Torpedo*), HYRTL (11).

There is an immense amount of variation in the mode of origin and in the distribution of the splanchnic arteries in Elasmobranchs. In the skate (11, 23) there are large coeliac and anterior mesenteric arteries and a small posterior mesenteric, or, more correctly, spermatico-mesenteric. In *Scymnus* (22), the large coeliac artery is supplemented by three small mesenteric arteries. In *Callorhynchus* there are two splanchnic arteries, a coeliaco-mesenteric and a posterior mesenteric, both of considerable size. In *Mustelus* and in *Torpedo* (11) the main arteries for the alimentary canal and its glands are branches of a coeliaco-mesenteric; in *Mustelus* there are, however, in addition three comparatively small vessels springing separately from the dorsal aorta; these I call, from their distribution, the lieno-gastric, and the anterior and posterior spermatico-mesenteric. Thus the names given to the more important splanchnic arteries of one Elasmobranch are often quite inapplicable to those of another, and I have found it impossible in many cases to use HYRTL'S names, since their employment would indicate homologies which do not exist.

The large and important cœliaco-mesenteric artery (Plate 34, fig. 1 ; Plate 35, figs. 6, 7, and 10 ; Plate 36, fig. 12, *Cœl. Mes. A.*) arises from the dorsal aorta immediately caudad of the junction with the latter of the fourth pair of epibranchial arteries. It is about 3 cm. long in the adult, dividing into sub-equal cœliac and mesenteric arteries.

The cœliac artery.

“An artery like to our cœliac,” MONRO (16).

Arteria cœliaca, HYRTL (11).

The anterior of the two divisions of the cœliaco-mesenteric artery (Plate 35, fig. 7 ; Plate 36, fig. 12, *Cœl. A.*) passes backwards along the inner or right side of the cardiac division of the stomach. It first gives off the *anterior gastric artery* (*Ant. gast. A.*) which supplies the proximal third of the dorsal wall of the cardiac division of the stomach ; then a comparatively small *right hepatic artery* (*R. hep. A.*) to the right lobe of the liver ; then a vessel which divides almost immediately into the *left hepatic artery* (*L. hep. A.*) supplying the left lobe of the liver, and the small pyloric artery (*Pyl. A.*) going to the distal end of the pyloric division of the stomach. The cœliac then becomes the main or *ventral gastric artery* (*Vent. gast. A.*), which branches out in the fold of mesentery between the cardiac and pyloric divisions of the stomach, sending numerous branches to both. Of these the branches to the cardiac division are distributed exclusively to its ventral wall.

The anterior mesenteric artery.

“An artery resembling our superior mesenteric artery,” MONRO (16).

Arteria mesenterica anterior, HYRTL (11).

This, the posterior division of the cœliaco-mesenteric artery (Plate 35, fig. 7 ; Plate 36, fig. 12, *Ant. Mes. A.*), passes backwards alongside the portal vein (fig. 12, *Hep. port. V.*) and divides, immediately cephalad of the pylorus, into a ventral branch, the *ventral intestinal artery*, and a dorsal branch, the *intra-intestinal artery*.

As far as its origin is concerned, this vessel clearly answers to the anterior mesenteric artery of the skate, but the further course of the latter vessel rather corresponds with that of the dorsal intestinal artery of *Mustelus* (*vide infra*, p. 700).

The ventral intestinal artery.

Duodenal artery (in *Scymnus* and *Raja*), PARKER (20, 22, and 23).

This trunk evidently corresponds, as far as its general relations are concerned, with that I have called duodenal in the skate and in *Scymnus*, since it lies ventrad of the duodenum or *bursa entiana*, supplying that part of the intestine. As, however, it originates in *Mustelus* from the anterior mesenteric artery instead of from the

coeliac as in the other two genera, and as, further, it supplies the ventral region of the intestine generally, it seems hardly desirable to retain the name "duodenal" for it.

After separating from the main stem of the anterior mesenteric, the ventral intestinal artery (Plate 35, fig. 7; Plate 36, fig. 12, *Vent. intest. A.*) curves round the dorsal aspect of the pylorus, between it and the intra-intestinal vein (*vide infra*, p. 705) and then passes on to the ventral face of the intestine, and so caudalwards alongside the ventral intestinal vein (p. 706), sending off transverse branches to the walls of the gut and to the folds of the spiral valve.

The intra-intestinal artery.

Intra-intestinal artery, PARKER (22).

As far as I am aware, the existence of this artery (*Int. intest. A.*) was first indicated by myself in a paper on the anatomy of *Scymnus lichia*. Leaving the main trunk of the anterior mesenteric artery, it curves round to the dorsal side of the intra-intestinal vein, sends off a small branch to the dorsal wall of the duodenum, and then comes to be enclosed, along with the corresponding vein (*infra*, p. 705), in the free edge of the spiral valve, to which it sends branches (fig. 12).

6. *The anterior spermatico-mesenteric artery.*

This (Plate 34, fig. 1; Plate 35, fig. 10; Plate 36, fig. 12, *Ant. sperm. mes. A.*) is a small artery arising from the dorsal aorta about 3 or 4 cm. caudad of the coeliaco-mesenteric. It passes almost directly backwards, crossing the origin of the lieno-gastric artery (*Li. gast. A.*), gives off the *anterior spermatic artery* to the gonad, and is continued as the *dorsal intestinal artery* (fig. 12, *Dors. intest. A.*), beside the corresponding vein, along the whole length of the dorsal aspect of the intestine, to which it gives off transverse branches corresponding to those of the ventral intestinal artery. The course of this vessel is thus much the same as that of the three mesenteric arteries of *Scymnus* (23), and of the great anterior mesenteric artery of *Raja* (16, 11, 23).

7. *The lieno-gastric artery.*

This vessel (Plate 34, fig. 1; Plate 35, fig. 10; Plate 36, fig. 12, *Li. gast. A.*) arises from the dorsal aorta immediately caudad of the anterior spermatico-mesenteric, the origin of which it crosses. It passes backwards and downwards alongside the anastomotic trunk between the spermatic and anterior lieno-gastric veins (*infra*, p. 708, figs. 1, 10, 12, and 13, *v*), sends off one or two small branches to the larger or free lobe of the pancreas, and reaches the dorsal wall of the cardiac division of the

stomach at about the junction of its third and fourth fifths. It then, as the *dorsal gastric artery* (*Dors. gas. A.*), branches out and supplies the posterior two-thirds of the dorsal wall of the cardiac division, a large *splenic artery* (*Spl. A.*) supplying the spleen and the posterior portion of the greater curvature of the stomach.

8. *The oviducal arteries.*

These vessels, existing only in the female, are large paired trunks (Plate 34, fig. 1, *Ovid. A.*) arising from the dorsal aorta about 6 cm. caudad of the celiaco-mesenteric artery. Each passes at first directly outwards, dorsad of the corresponding cardinal vein, then turns sharply backwards, divides into an anterior and a posterior branch, and ramifies in the wall of the oviduct.

9. *The posterior spermatico-mesenteric artery.*

Figured but not named (in *Raja*), by MONRO (16).

Arteria mesenterica posterior, HYRTL (11).

This is a comparatively small vessel (Plate 34, figs. 1 and 3, *Post. sperm. mes. A.*). It passes backwards and downwards, pierces the posterior azygos lobe of the gonad (ovary or testis)* which it supplies, and reaches the anterior or free end of the rectal gland (figs. 3 and 12, *Rect. Gl.*) as the *posterior mesenteric artery* (*Post. mes. A.*) in the strict sense. It then extends caudalwards along the whole dorsal border of the rectal gland, sending out numerous branches right and left.

10. *The spinal (segmental) arteries.*

From the whole length of the dorsal aorta, including its hyoidean section, small arteries are given off right and left, corresponding to the vertebral segments, and supplying the dorsal muscles.

11. *The renal arteries.*

These, like the preceding, are given off segmentally from the dorsal aorta. In the male the parorchis (WOLFFIAN body or mesonephros) is similarly supplied.

12. *The iliac arteries.*

These arteries (Plate 34, figs. 1 and 3, *Il. A.*) arise from the dorsal aorta a short distance cephalad of the level of the pubic cartilage. Each passes outwards and

* In *Mustelus antarcticus* there is a single ovary in the female, but the male has two testes which coalesce posteriorly into a single lobe.

backwards, and divides into a *femoral artery* (*Fem. A.*) distributed to the pelvic fin, and a *posterior lateral artery* (*Post. lat. A.*) which extends forwards, accompanying the lateral vein, and contributing to the supply of the abdominal walls.

13. *The caudal artery.*

At the commencement of the hæmal canal of the caudal vertebræ, the dorsal aorta becomes the caudal artery (Plate 34, fig. 1; Plate 37, fig. 25, *Caud. A.*), which passes to the end of the tail, supplying its various tissues.

II. THE VEINS.

The investigation of the veins of Elasmobranchs is attended with so much more difficulty than that of the arteries, that it is hardly surprising to find the published accounts of them generally wanting in detail, besides being actually inaccurate in many particulars.

The veins of *Mustelus* may be classified, mainly on embryological grounds, as follows :—

- A. System of the sub-intestinal vein.
 - i. Renal portal section.
 1. The caudal vein.
 2. The renal portal veins.
 - a. The posterior oviducal veins.
 - b. The posterior spinal veins.
 - ii. Hepatic portal section.
 3. The hepatic portal vein.
 - a. The intra-intestinal vein.
 - b. The ventral intestinal vein.
 - c. The posterior lieno-gastric vein.
 - d. The gastro-intestinal vein.
 - a. The dorsal intestinal vein.
 - β. The anterior lieno-gastric vein
 - γ. The anterior gastric vein.
 - e. The ventral gastric vein.
 4. The hepatic veins and sinus.

- B. System of the cardinal veins.
5. The precaval sinuses.
 - a. The jugular veins.
 - α. The orbital sinuses.
 - i. The anterior facial veins.
 - ii. The anterior cerebral veins.
 - β. The hyoidean sinuses.
 - i. The posterior facial veins.
 - ii. The nutrient hyoidean veins.
 - b. The inferior jugular veins.
 - a. The nutrient branchial veins.
 - c. The cardinal veins.
 - a. The renal veins.
 - β. The spermatic veins.
 - γ. The anterior oviducal veins.
 - δ. The anterior spinal veins.
 - ε. The posterior cerebral veins and the myelonal vein.
 - ζ. The subscapular veins.
- C. System of the lateral veins.
6. The lateral veins.
 - a. The brachial veins.
 - b. The iliac veins.
 - α. The femoral veins.
 - β. The cloacal veins.
- D. System of the coronary veins.
7. The coronary veins.
- E. System of the cutaneous veins.
8. The dorsal cutaneous vein.
 9. The anterior ventral cutaneous vein.
 10. The posterior ventral cutaneous vein.
 11. The lateral cutaneous veins.

A. i. *System of the sub-intestinal vein : renal portal section.*

1. *The caudal vein.*

Vena caudalis, STANNIUS (25).

Veine caudale, MILNE EDWARDS (14).

Caudal vein, HUXLEY (10), CLAUS (4), &c., &c.

The caudal vein (Plate 34, figs. 1 and 3 ; Plate 37, fig. 25, *Caud. V.*) lies in the hæmal canal immediately ventrad of the caudal artery. It receives the lesser

veins from the tissues of the tail, and, on leaving the hæmal canal, divides, at the level of the posterior extremity of the kidneys, into the symmetrical (right and left) renal portal veins.

2. *The renal portal vein.*

Veine porte rénale, Veine de Jacobson, JOURDAIN (12).

Renal portal vein, ROLLESTON (24), PARKER (21, 23).

It is somewhat remarkable, considering that the elaborate researches of JOURDAIN (12) appear in so well-known a journal as the "Annales des Sciences Naturelles," that the existence of a true renal portal vein in Elasmobranchs is either ignored or expressly denied by the writers of all the more important zoological text-books with the single exception of ROLLESTON (24). STANNIUS (25), MILNE EDWARDS (14), on the authority of HYRTL, HUXLEY (10), GEGENBAUR (7), MACALISTER (13), and CLAUS (4) all state explicitly that in Elasmobranchs, as in Cyclostomes, the caudal vein opens directly into the cardinals. MACALISTER certainly states that branches from the cardinal veins enter the kidneys, forming a reno-portal capillary plexus, and GEGENBAUR mentions the existence of similar *venæ renales advehentes* as branches of the caudal. But neither author gives a sufficiently detailed account to enable the reader to understand what the exact relations of the renal portal system are supposed to be.

As a matter of fact JOURDAIN, following up the earlier researches of JACOBSON, ROBIN, STEENSTRA TOUSSAINT, and others,* has clearly proved the existence of a renal portal system in *Raja*, *Squatina*, *Squalus*, and *Spinax*, in all of which he shows there to be no direct passage for blood between the caudal and the cardinal veins in the adult. I have confirmed JOURDAIN's results in *Raja nasuta* (21, 23), and now find that they hold good also for *Mustelus antarcticus*.

The renal portal veins (Plate 34, figs. 1 and 3; Plate 37, figs. 22, 23, 24, *Ren. port. V.*) formed, as stated above, by the bifurcation of the caudal vein, pass forwards each along a groove on the dorsal aspect of the corresponding kidney, sending off numerous *afferent renal veins* (*venæ renales advehentes*) into the substance of the gland, and gradually diminishing in calibre towards its anterior end (*cf.* figs. 24, 23, and 22, *Ren. port. V.*).

The *spinal* (segmental) *veins* from the posterior abdominal region of the vertebral column and the posterior *oviducal veins* from the hinder moiety of the oviduct

* JACOBSON, 'MECKEL'S Archiv,' vol. 3, 1817, p. 147; and "De systemate venoso peculiari in permultis animalibus observato," Hafniæ, 1821. STEENSTRA TOUSSAINT, "Comment. de syst. uropoët. piscium," 'Ann. Acad. Lugd.-Batav.,' 1834-35; and "De syst. uropoët. Squali glauci," 'Hoeven en Vriese, Tijdschrift,' vol. 6, 1839, p. 199. ROBIN, "Note sur quelques portions du système veineux des Raies," 'Revue Zool.,' vol. 9, 1846, p. 5. OWEN, "Lectures on the comparative Anatomy and Physiology of the Vertebrate Animals," I., 1846, p. 284. (Quoted by JOURDAIN in 12.)

discharge into the renal portal veins: the vein of the left side also receives the dorsal cutaneous vein (*infra*, p. 720).

A. ii. *System of the sub-intestinal vein: hepatic portal section.*

3. *The hepatic portal vein.*

Pfortaderstamm, STANNIUS (25).

Veine porte hépatique, MILNE EDWARDS (14).

Portal arterial vein, OWEN (19).

Vena portæ, HUXLEY (10).

The hepatic portal vein, or portal vein as it is more usually called (Plate 36, figs. 12 and 13, *Hep. Port. V.*), is a large vessel, fully 12 mm. in diameter when distended with injection, and lying in the gastro-hepatic omentum side by side with the anterior mesenteric artery. It is formed, at about the level of the pylorus, by the confluence of the intra-intestinal (*Intr. intest. V.*), ventral intestinal (*Vent. intest.*), and posterior lieno-gastric (*Post. li. gast. V.*) veins; somewhat caudad of the cardia it receives the gastro-intestinal (*Gast. intest. V.*) and ventral gastric (*Vent. gas. V.*) veins; on reaching the liver it divides into two main branches, one for each lobe, besides sending off one or two lesser branches into the central portion of the gland.

The intra-intestinal vein.

Tronc veineux mésentérique (in *Thalassorhina* and *Zygæna*), DUVERNOY (6).

Partie postérieure du tronc principal de la veine porte, ou veine mésentérique (in *Zygæna*, &c.), MILNE EDWARDS (14).

Main root of the portal vein ("in Plagiostomes with the longitudinal spiral valve"), OWEN (19).

Darmvene ("bei Petromyzon und einigen Squaliden"), STANNIUS (25).

Intestinal vein (in Cyclostomes), MACALISTER (13).

A special vein which lies in the fold of the spiral valve, BALFOUR (2).

Intra-intestinal vein, PARKER (22).

This, one of the most interesting vascular trunks from a morphological point of view, was discovered fifty years ago by DUVERNOY in *Galeus* (?) *thalassinus* (? *Thalassorhinus*) and *Zygæna malleus*, and was afterwards shown to exist also in *Carcharias* and *Galeocerdo*; all four genera of Selachians possessing a "scroll-valve" (20) instead of the ordinary spiral valve. DUVERNOY showed that the principal intestinal vein in these cases was a large vessel, with thick muscular walls, enclosed within the free border of the longitudinally rolled scroll-valve, and forming the chief factor of the portal vein.

Special significance was given to this vein by BALFOUR's discovery (1) that it is

formed from the pre-caudal portion of the sub-intestinal vein or primitive ventral vascular trunk of the embryo. It is usually stated, for instance by MÜLLER (17), STANNIUS (25), and MILNE EDWARDS (14), to be absent in those genera in which a true spiral valve is present, but has been shown by myself (22) to exist as a large and conspicuous trunk both in the species now under consideration and in *Callorhynchus antarcticus*.

The intra-intestinal vein of *Mustelus* (Plate 36, figs. 12 and 13; Plate 37, figs. 22 and 30, *Int. intest. V.*) is a large vessel, fully 8 mm. in diameter at its anterior end when moderately distended with injection. It lies imbedded in the free edge of the spiral valve, having therefore itself a spiral twist, and is accompanied by the intra-intestinal artery. It receives veinlets from the inner or central portions of the various turns of the spiral valve, emerges through the wall of the intestine (fig. 12) immediately dorsad of the pylorus, receiving as it does so a small *duodenal vein* (*Duod. V.*) from the dorsal wall of the duodenum, and finally joins the ventral intestinal and posterior lieno-gastric veins about 2-3 cm. to the right, and dorsad of the pylorus.

The ventral intestinal vein.

Duodenal vein (in *Raja* and *Scymnus*), PARKER (20-23).

This, the second large vein of the intestine (Plate 36, figs. 12 and 13; Plate 37, figs. 22, 30, *Vent. intest. V.*), accompanies the artery of the same name, receiving transverse feeders from the walls of the gut, and from the outer or peripheral portions of the successive turns of the spiral valve. In the greater part of its course it is double, the two divisions lying one on each side of the artery. Anteriorly it passes to the left, between the intestine and the narrow pyloric division of the stomach, and finally turns immediately caudad of the pylorus to join the intra-intestinal and posterior lieno-gastric veins.

The posterior lieno-gastric vein.

This (Plate 36, figs. 12 and 13, *Post. li. gast. V.*) is a moderate-sized vessel lying between the pyloric division of the stomach and the adjacent right lobe of the spleen, and receiving feeders from both. Anteriorly it passes dorsad of the pylorus to join with the two preceding vessels as already described.

The gastro-intestinal vein

(Plate 36, figs. 12 and 13, *Gast. intest. V.*) is a large vessel lying parallel to and dorsad of the main portal vein, and joining the latter about 6 cm. cephalad of the pylorus. Posteriorly it is constituted by the confluence of the dorsal intestinal

(*Dors. intes. V.*) and anterior lieno-gastric (*Ant. li. gast. V.*) veins, while immediately before joining the portal it receives the anterior gastric vein (*Ant. gast. V.*).

The dorsal intestinal vein.

Mesenteric vein (in *Raja* and *Scymnus*), PARKER (20-23).

The remarks made above (p. 698), as to the absence of any close correspondence between the splanchnic arteries of different Elasmobranchs, apply equally well to the veins. In *Raja* (21, 23) nearly the whole of the blood from the intestine is returned by a large mesenteric vein, lying dorsally and somewhat to the left, this being supplemented by small duodenal (ventral intestinal) and intra-intestinal veins; these, together with the splenic and pancreatic veins, unite to form a common trunk which is afterwards joined by the gastric veins. The mesenteric vein, from its position, evidently answers to the vessel now under consideration in *Mustelus*. In *Scymnus* (22) the duodenal (ventral intestinal) vein has become as large as the mesenteric (dorsal intestinal); the two unite with one another, the mesenteric previously receiving a large lieno-gastric vein, and into the common portal vein thus formed the remaining gastric veins are discharged.

In *Mustelus* the blood is returned from the intestine by no fewer than three veins, each as large proportionally as the single mesenteric vein of *Raja*. Two of these, as already seen, unite with one another and with the posterior lieno-gastric; the third, the dorsal intestinal vein now under discussion (Plate 37, figs. 12 and 13, *Dors. Intest. V.*) commences on the ventral or free border of the rectal gland, where it anastomoses with the posterior oviducal, spermatic, and cloacal veins (Plate 34, fig. 3), and apparently receives most of the blood from the posterior extremity of the gonad. As far as my observations go, I am disposed to consider this relation with the rectal gland as constant for the dorsal intestinal vein of Plagiostomes.

Passing forwards, the dorsal intestinal vein receives transverse factors from the walls of the intestine and outer regions of the turns of the spiral valve; these probably anastomose both with those of the corresponding feeders of the ventral intestinal and with those of the intra-intestinal vein.

In the position actually assumed by the intestine in the adult fish the dorsal intestinal vein, through a considerable part of its course, lies on the left side, the ventral intestinal on the right (Plate 37, fig. 22). But as the former trunk is a continuation, forwards, of the line of the rectal gland and mesorectum, *i.e.* the line along which the mesentery, if present, would be attached, it is morphologically dorsal in position.

Arrived at the posterior boundary of the duodenum, or in other words at the junction between the first and second turns of the spiral valve, the dorsal intestinal vein leaves the wall of the gut (fig. 12), and, still accompanied by the corresponding artery, passes dorsalwards, supported by a fold of mesentery, to the posterior

end of the free or dorsal lobe of the pancreas. From the latter it receives small *pancreatic veins*, and finally unites with the anterior lieno-gastric to form the gastro-intestinal vein at about the level of the pylorus.

The anterior lieno-gastric vein

(Plate 36, figs. 12 and 13, *Ant. li. gast. V.*) accompanies the lieno-gastric artery, receiving the blood from the posterior two-thirds of the dorsal wall of the cardiac division of the stomach and from the larger or left lobe of the spleen. As mentioned above it unites with the dorsal intestinal vein at about the level of the pylorus, forming the gastro-intestinal vein.

In connexion with this vein there is a very remarkable anastomosis placing the portal circulation in direct and open communication with the ordinary systemic veins. This consists of a vessel (Plate 34, fig. 1; Plate 35, fig. 10; Plate 37, figs. 12 and 13, *v*), accompanying the proximal portion of the lieno-gastric artery, opening ventrally into the anterior lieno-gastric vein close to its junction with the dorsal intestinal, and communicating dorsally with the spermatic vein near its junction with the right cardinal.

The anterior gastric vein

(Plate 36, figs. 12 and 13, *Ant. gast. V.*) accompanies the artery of the same name, bringing blood from the proximal third of the dorsal wall of the cardiac division of the stomach. It enters the gastro-intestinal vein shortly before its junction with the portal.

The ventral gastric vein.

This (Plate 36, figs. 12 and 13, *Vent. gast. V.*) is the largest of the gastric veins, receiving the blood from the whole ventral region of the cardiac division. It accompanies the ventral gastric artery and opens into the portal vein about 2 cm. cephalad of the junction with it of the gastro-intestinal vein.

4. *The hepatic veins and sinus.*

a. Hepatic veins.

Venæ cavæ hepaticæ, MONRO (16).

Veines hépatiques, MILNE EDWARDS (14).

b. Hepatic sinus.

Receptacle formed by the venæ cavæ hepaticæ, MONRO (16).

Hepatic sinus, PARKER (21 and 23).

The blood supplied to the liver by the hepatic arteries and portal vein is collected into two immense hepatic veins (Plate 35, fig. 9; Plate 37, figs. 21 and 22, *Hep. V.*),

imbedded one in the right the other in the left lobe, and opening anteriorly into the hepatic sinus (*Hep. S.*).

The latter is a capacious chamber lying immediately cephalad of the liver and ventrad of the oesophagus. When distended with blood or injection it completely fills the antero-ventral region of the coelome, abutting in front against the pericardio-peritoneal septum (*Peric. perit. Sept.*), while posteriorly it adapts itself to the anterior border of the liver. Its general relations to surrounding parts are best seen in transverse and horizontal sections of a frozen fish (Plate 35, fig. 9 ; Plate 37, figs. 19, 20, and 21).

Internally the hepatic sinus is divided into right and left compartments by an incomplete vertical partition (*p*) formed of an irregular network of fibrous trabeculae. Each compartment is also traversed by numerous irregular fibrous bands. The hepatic veins open each into the compartment of its own side by a large aperture.

The hepatic sinus opens into the sinus venosus by two small circular apertures (*Hep. S'*), placed close together in its anterior wall one on each side of the median partition.

It will be seen from the above description that the relations of the "system of the sub-intestinal vein" to the embryonic trunk from which it takes its origin is remarkably clear in *Mustelus antarcticus*. We have, first, the caudal vein, the relations of which are only disturbed by the atrophy of the post-anal gut; this is followed, after a short interruption of continuity, by the intra-intestinal, which is directly continued into the main portal vein; then the continuity of the original vessel is again interrupted, this time by the capillaries of the liver, following which we have the paired hepatic veins opening by the hepatic sinus into the heart. There is thus a successive series of longitudinal trunks, all unpaired, except the hepatic veins, indicating, in the adult, the course of the originally continuous sub-intestinal vein of the embryo.

In this, as in so many points, the Sharks exhibit a more generalized type of structure than the Rays. Besides the retention of a large intra-intestinal vein in many Selachians, the hepatic sinus in *Raja* has no direct communication with the sinus venosus, but opens by two widely separated apertures into the two precaval sinuses (*see* 16 and 21, or 23).

B. *System of the cardinal veins.*5. *The precaval sinus.*

Described and figured, but not named, by MONRO (16).

Truncus transversus, Ductus Cuvieri, STANNIUS (25).

Canal de Cuvier, MILNE EDWARDS (14).

Precaval vein, OWEN (19).

Ductus Cuvieri, HUXLEY (10), ROLLESTON (24), GEGENBAUR (7).

Cuvierian duct, MACALISTER (13).

Precaval sinus, PARKER (21 and 23).

The paired precaval sinuses are the homologues of the great precaval veins or Cuvierian ducts of Teleosts and of the precaval veins or venæ cavæ anteriores s. superiores of the higher Vertebrata. Owing to their form the name of sinus is more applicable to them than that of vein in Elasmobranchs.

The precaval sinus of *Mustelus* (Plate 34, figs. 1 and 2; Plate 35, figs. 9 and 10; Plate 37, figs. 19, 27, and 28, *Pr. cav. S.*) is a tubular chamber, about 15 mms. long and 5 mms. wide, situated immediately laterad of (external to) the sinus venosus, of which, on anatomical grounds alone, it might be looked upon as merely an extra-pericardial portion. From its junction with the sinus venosus it takes a direction upwards and outwards (fig. 19), its antero-lateral wall lying in close apposition to the fifth branchial arch (fig. 10) at the junction of the epi- and ceratobranchial, while its inner wall is closely applied to the œsophagus. Its precise relations are best seen in transverse and horizontal sections of frozen specimens (figs. 9 and 19), in which also the apertures of the various veins into the sinus are well displayed.

There is no constriction between the precaval sinus and the sinus venosus, the boundary between the two being marked only by a very low inconspicuous ridge in the lining membrane and by the position of the pericardial wall. Dorsally the precaval sinus passes with but slight change of diameter into the jugular vein, the entrance of which (figs. 2, 9, and 19, *Jug. V'*.) is guarded by a pair of semilunar valves; these act so perfectly that I have never known even a drop of injection to pass from the sinus into the vein. In the posterior wall of the precaval sinus is the large valveless aperture of the cardinal sinus (*Card. S'*.); on its ventral wall, close to its junction with the sinus venosus is a small aperture communicating with the lateral vein (*Lat. V'*.), and, lastly, in its antero-ventral region in the somewhat larger opening of the inferior jugular vein (*Inf. Jug. V'*.).

The jugular vein.

Internal jugular vein, MONRO (16).

Vena jugularis superior, MÜLLER (17).

Vena vertebralis anterior s. jugularis, STANNIUS (25),

Veines jugulaires, MILNE EDWARDS (14).

Vena jugularis, OWEN (19), HUXLEY (10), ROLLESTON (24).

Jugular vein, MACALISTER (13), GEGENBAUR (7).

As in the case of the carotid arteries (*supra*, p. 699) there is no precise correspondence between the cephalic veins of fishes and the "internal" and "external" jugulars of the higher animals. In position the vein now under consideration agrees, as MONRO saw, with the internal jugular, from which, however, it differs in receiving the main part of the blood from the whole head, and not only that from the brain.

The jugular vein (Plate 34, figs. 1 and 2 ; Plate 35, figs. 9 and 10 ; Plate 37, figs. 18, 26, and 27, *Jug. V.*) is a very large vessel, about 1 cm. in diameter, and triangular in section (fig. 18), situated immediately dorsad of the gills and laterad of the dorsal muscles. Anteriorly it lies in the horizontal plane of the auditory capsule (fig. 10), posteriorly in that of the œsophagus (fig. 19), so that it takes a direction from its cephalic end backwards and slightly downwards.

At its posterior extremity, as already stated above, the jugular turns downwards, caudad of the fifth branchial arch (fig. 10), to enter the precaval sinus, the junction between the two being marked by a pair of transversely-placed semilunar valves (figs. 2 and 19).

At its cephalic end the jugular becomes a somewhat irregular channel (fig. 10), and passes laterad of the auditory capsule, narrowing considerably in vertical height as it does so, and at the same time becoming wider from side to side. It is this portion of the jugular which receives the blood from the orbital sinus anteriorly, and that of the hyoidean sinus ventrally (*vide infra*). Throughout its whole length the jugular receives feeders from the dorsal region of the gills and other neighbouring parts.

The orbital sinus.

Situated within the orbit and surrounding the eye-muscles is a large irregular sinus (Plate 35, fig. 10, *Orb. S.*), always containing more or less blood in the freshly-dissected fish. When the eye and its muscles are removed, there is seen, in the posterior wall of the orbit, a small depression, bounded externally by a ligament, alongside and parallel with which is the hyomandibular nerve or posterior division of the seventh; this depression leads by a narrow oblique passage from the orbital sinus into the jugular vein, the aperture between the two being guarded by a distinct valve.

The orbital sinus receives the anterior cerebral vein (*infra*), and at the anterior (*inner*) canthus of the orbit a vein from the anterior and external region of the head

(*anterior facial vein, Ant. fac. V.*) is apparently discharged into it; but I have never been able to get a satisfactory injection of this vessel.

The only reference to the orbital sinus I have met with is the following somewhat obscure statement given by MILNE EDWARDS (14) on the authority of ROBIN, whose paper* I have unfortunately been unable to consult. "Les veines jugulaires communiquent entre elles par un tronc anastomotique assez large, et constituent en général, derrière les orbites, un sinus plus ou moins vaste Il est extrêmement développé chez les Squales, et constitue de chaque côté des branchies un vaste réservoir qui s'étend dans les cavités orbitaires." This paragraph would seem to intimate that the anterior ends of the jugular veins communicate directly with one another, which they certainly do not in *Mustelus*; indeed, from their position, any such union is anatomically impossible.

The anterior cerebral vein.

This (Plate 35, fig. 8, *Ant. cerebr. V.*) is a paired vein receiving the blood from the olfactory lobe, and from its own side of the prosencephalon, diencephalon, and mesencephalon. At the level of the diencephalon it turns directly outwards, passes through a foramen in the side wall of the skull, and discharges itself into the orbital sinus.

The blood from the rest of the brain is returned by the posterior cerebral veins which will be considered later (p. 715).

The hyoidean sinus.

This (Plate 34, fig. 2; Plate 35, fig. 10, *Hyoïd. S.*) is a wide irregular vessel lying on the outer face of the hyoid arch, parallel to the first afferent branchial artery (*Af. br. A. 1*). In the middle part of its course it is double, consisting of two parallel trunks which unite with one another above at about the level of the junction of the epi- and cerato-hyal, below at that of the junction of the cerato- and hypo-hyal.

The hyoidean sinus discharges into the interior end of the jugular vein by an aperture on its ventral wall, guarded by a single valve. Ventrally it is continued forwards to the symphysis mandibulæ, parallel to and mesiad of the sub-mental artery, this portion of the sinus being the equivalent of a *sub-mental vein*.

The right and left hyoidean sinuses communicate with one another by two wide anastomotic trunks (fig. 2, *u*), one immediately cephalad, the other immediately caudad, and both of them ventrad of the common stem of the first and second afferent branchial arteries. Close to the junction of the hindermost of these anastomotic trunks the inferior jugular vein (*Inf. jug. V.*) communicates with the hyoidean sinus.

* ROBIN, "Sur le système veineux des poissons cartilagineux," 'Compt. Rend.,' vol. 21, 1845, p. 1282.

The chief tributaries of the hyoidean sinus are—(a) veins from the mandible entering its ventral or submental portion; (b) several nutrient veins from the hyoidean hemibranch (fig. 10, *Nu. hy. V.*); and (c) a vein (*Post. fac. V.*) entering near the junction of the hyomandibular and cerato-hyal which I have been able to trace only for a very short distance; probably it is safe to call it the *posterior facial vein*.

The inferior jugular vein.

A small vein somewhat like to our anterior external jugular, MONRO (16).

Vena jugularis inferior, MÜLLER (17), STANNIUS (25).

The inferior jugular veins (Plate 34, figs. 1 and 2; Plate 35, fig. 10; Plate 37, figs. 18, 26, and 27, *Inf. jug. V.*) are moderately-sized vessels, lying, one on each side, at the base of the gills, about 1–2 cm. laterad of the ventral aorta. Each anastomoses in front with the corresponding hyoidean sinus, and passing backwards, receives the nutrient veins of the four holobranchs. After receiving the last of these, the inferior jugular is deflected somewhat outwards and comes to lie in the roof of the pericardial cavity immediately mesiad of and parallel with the fifth cerato-branchial, finally entering the precaval sinus by the aperture already noticed.

In an embryo of *Scymnus lichia*, referable to "Stage O" of BALFOUR (1, Plate VIII., figs. O, O'), the inferior jugulars are already large vessels, and, along with the jugulars, open by wide valveless apertures into the short precaval sinuses (Plate 37, figs. 27 and 27).

The nutrient branchial veins.

Venæ bronchiales, MÜLLER (17).

Veines de Duvernoy, MILNE EDWARDS (14).

Of these there are four on each side, one for each holobranch (Plate 34, fig. 2; *Nu. Br. V.*, 1–4). The first three are similarly situated, being parallel to the ventral portion of the extra-branchial cartilage and to the nutrient branchial artery; in each case the vein is anterior, the cartilage posterior, and the artery intermediate in position. The fourth nutrient vein takes a somewhat different course, lying mainly on the posterior face of the gill. They are connected with a rich plexus of veins.

*The cardinal veins.**Abdominal cava, vena cava*, MONRO (16).*Vertebralvene*, MÜLLER (17).*Vena vertebralis posterior*, STANNIUS (25).*Veine abdominale*, MILNE EDWARDS (14),*Vena cardinalis*, OWEN (19).*Cardinal vein*, HUXLEY (10).

The cardinal veins (Plate 34, fig. 1 ; Plate 35, fig. 10 ; Plate 37, figs. 22, 23, and 24, *Card. V.*) lie immediately ventrad of the vertebral column. They are unsymmetrically developed, the right trunk (*R. Card. V.*) only being complete, and the left (*L. Card. V.*) uniting with it a short distance caudad of the anterior end of the kidneys. Posterior to the point of union with its fellow the right cardinal is situated in the middle line imbedded in the fused kidneys (figs. 23 and 24), and therefore not visible in the ordinary course of dissection without partly removing the latter ; traced backwards it is found to undergo a gradual diminution in calibre, and to arise at the posterior end of the kidneys by the confluence of the efferent veins from that part of the renal tissues.

It has already been shown (*supra*, p. 703) that the caudal vein, contrary to the statements usually made, divides into two renal portal veins which pass forwards, gradually diminishing in calibre. It is now shown that the cardinal vein, so far from being continuous with the caudal, commences as a very small vessel in the posterior region of the kidneys, and extends forwards, gradually increasing in calibre. These facts are clear enough from ordinary dissection ; if an injected specimen be hardened in alcohol, the cardinal vein slit open longitudinally and the contained injection-mass removed, the non-extension of the vein caudad of the kidneys is perfectly evident. But the matter becomes clearer still by the examination of a series of sections, as shown in Plate 37, figs. 22-24. In fig. 22, taken through the middle of the first dorsal fin and a short distance cephalad of the union of the left cardinal with the right, the renal portal veins are very small ; in fig. 23, taken 4 cms. cephalad of the pubis, the right cardinal is seen to have taken up a median position and the renal portals have increased in size ; in fig. 24, through the symphysis pubis, the renal portals have still further increased in calibre and are now distinctly larger than the right cardinal, which, in the next section, had disappeared.

It will be for future investigations to determine the age at which the formation of the renal portal system takes place, all that can be said at present being that it occurs during comparatively late embryonic life. In the embryo of *Scymnus*, already referred to ("Stage O," BALFOUR), the caudal vein is directly continued into the cardinals as in Cyclostomes (Plate 37, figs. 31 and 32) ; on the other hand, in a ripe foetus of *Mustelus* I have ascertained, from a complete series of

thin sections of the pelvic region, that the adult condition of things is already fully established.

Tracing the cardinals forward from the point of union of the left with the right, each is seen to dilate into a large cavity, the *cardinal sinus* (Plate 34, figs. 1 and 2; Plate 35, figs. 9 and 10; Plate 37, figs. 19-21, *Card. S.*) which opens into the corresponding precaval sinus as already described (p. 710). The two cardinal sinuses communicate with one another by a wide oval aperture (fig. 10, *ap.*) close to the entrance of the spermatic vein (*Sperm. V.*).

The cardinal veins receive the *efferent renal veins* from the kidneys, and, in the anterior half of the abdomen, the *oviducal* and the *spinal* (segmental) *veins*. The posterior oviducal and spinal veins, as already stated, open into the renal portal veins.

The spermatic vein.

This (Plate 34, fig. 1, Plate 35, fig. 10, *Sperm. V.*) is a very large and capacious vessel, deserving rather to be called a sinus than a vein in the adult. It receives the blood from all but the posterior extremity of the ovary or testes (see p. 707), and opens into the conjoined portion of the cardinal sinuses. Close to its entrance the spermatic vein receives the large anastomotic trunk (*v*) from the anterior lieno-gastric vein (*supra*, p. 708).

The posterior cerebral and myelonal veins.

The veins from the anterior part of the brain, *i.e.*, as far back as the mesencephalon, have been seen (p. 712) to pour their blood, by the symmetrical anterior cerebral veins, into the orbital sinuses. The veins from the cerebellum and medulla oblongata unite to form on each side a *posterior cerebral vein* (Plate 35, fig. 8, *Post. cerebr. V.*), which lies dorso-laterad of the medulla. About 0.5 cm. caudad of the calamus scriptorius the two posterior cerebral veins unite with one another, on the dorsal surface of the spinal cord, to form the *myelonal vein* (*Myel. V.*) which extends backwards along the whole length of the cord. In each vertebral segment this vessel forms a small simple rhomboidal plexus, from the lateral angles of which commissures are given off, and, passing outwards and downwards, discharge into either the jugular, the cardinal, the renal portal, or the caudal vein. There is thus a series of segmentally arranged commissures between the myelonal vein on the one hand, and one of the sub-vertebral series of veins on the other. The commissures receive also feeders from the dorsal muscles.

The subscapular sinus.

The subscapular sinus (Plate 34, fig. 1, Plate 36, fig. 16, Plate 37, fig. 21, *Subscap. S.*) is a capacious vessel situated immediately mesiad of the scapula, *i.e.*, between it and

the underlying muscles; it receives vessels from the neighbouring parts, as well as the lateral cutaneous vein (*infra*, p. 721), and, passing forwards and inwards, discharges into the cardinal sinus.

The œsophageal veins.

These form a close plexus, resembling that of the mammalian gravid uterus; they open on each side, by small apertures in its inner wall, into the cardinal sinus.

C. *System of the Lateral Veins.*

6. *The Lateral Vein.*

(Anterior part only.) *A large vein from the abdominal muscles and side of the fish*, MONRO (16).

Gros vaisseau lymphatique sous-péritonéal, vaisseau latéral, ROBIN, quoted by MILNE EDWARDS (15).

Ilio-hæmorrhoidal plus Epigastric vein, PARKER (21 and 23).

Lateral vein, PARKER (22).

The lateral vein (Plate 34, figs. 1-3; Plate 35, figs. 9 and 10; Plate 37, figs. 20-24, *Lat. V.*) is a vessel of considerable size lying in the side wall of the abdomen immediately external to the peritoneum, and passing from the level of the pelvic fin forwards and upwards to the level of the pectoral. Posteriorly it unites with its fellow across the dorsal face of the pubic cartilage (figs. 1, 3, and 24); anteriorly it turns inwards or towards the middle line, and then forwards, outwards, and upwards, to open into the precaval sinus (*supra*, p. 710, figs. 1, 2, 9, and 19). It receives veins from the abdominal walls, as well as from the pectoral and pelvic fins (*infra*, p. 717), and anastomoses with the anterior ventral cutaneous vein (p. 720).

The anterior moiety of the lateral vein of the Skate is figured by MONRO (16, Plate III.), who, however, only traced it a short distance backwards. ROBIN* seems to have been the first to notice the veins in their entirety, but he apparently missed their connexion with the brachial and femoral veins, as well as with the precaval sinus; he also originally described them as lymphatics, but afterwards, finding them to contain blood, was led to consider them as veins.† They were re-discovered by myself in the Skate (21), and were subsequently found to exist in *Scymnus*, *Acanthias*, *Mustelus*, and *Chiloscyllium* (22). In recording their presence in the last named genera I remarked that, although I had found no account of them, it was difficult to believe such large vessels to have escaped notice; it had not occurred to me at that time to consult the section on the lymphatic system in MILNE EDWARDS'S "Leçons," and no mention of the lateral veins is made under the head of the venous system.

* ROBIN, "Revue Zoologique" de GUÉRIN, 1845, p. 225.—Quoted by MILNE EDWARDS (15, p. 477).

† ROBIN, "Note sur le système sanguin et lymphatique des Raies et des Squales," 'L'Institut,' vol. 13, 1845, p. 452.—Quoted by MILNE EDWARDS (15, p. 472).

The brachial vein.

The brachial vein (Plate 34, figs. 1 and 2, Plate 35, fig. 10, Plate 37, figs. 20 and 21, *Brach. V.*), receiving the blood from the pectoral fin, lies parallel with and immediately mesiad of the metapterygium; at its anterior end it turns inwards, and opens into the lateral vein close to its junction with the precaval sinus.

The iliac vein.

This (Plate 34, figs. 1 and 3, Plate 37, fig. 24, *Il. V.*) is a short trunk formed by the union of the cloacal and femoral veins (*infra*); it receives an anastomotic branch from the anterior ventral cutaneous vein (figs. 3 and 14), and opens into the lateral vein near the articulation of the basipterygium with the hip-girdle (fig. 24).

The femoral vein

(Plate 34, figs. 1 and 3, *Fem. V.*) lies immediately dorsad of the basipterygium. It receives factors from the substance of the fin, and, in the male, from the clasper.

The cloacal vein

(Plate 34, figs. 1 and 3, *Clo. V.*) takes a course nearly parallel to the preceding. It receives several large vessels from the cloaca, the anterior of which are also fed by factors from the rectum, oviduct, and ovary. Thus the cloacal veins anastomose with the mesenteric, spermatic, and oviducal veins. Posteriorly the two cloacal veins receive the blood from the posterior ventral cutaneous vein (figs. 3 and 14).

I think there can be no doubt that the lateral veins, which may now be fairly considered as characteristic of Plagiostomes, are homogeneous with the epigastric or anterior abdominal veins of Amphibians and Reptiles. When first suggesting this homology (21) I was unaware of the support afforded to the determination by the facts of embryology. In *Amphibia* (2, p. 539) there are in the embryo two epigastric veins which open in front into the sinus venosus, while posteriorly they are connected with the iliac veins, and also receive factors from the allantoic bladder and rectum. Reference to fig. 1 shows that a very slight shifting of the proximal end of the brachial vein would make it open separately into the precaval sinus (anterior vena cava), while a displacement mesiad of not more than one or two millimetres would cause the lateral vein to open directly into the sinus venosus.

I have elsewhere (21 and 22) advanced the hypothesis that the lateral vein may be looked upon as derived from the vein of the continuous lateral fin of the ancestral vertebrate, from which, according to the BALFOUR-THACHER theory, the limbs of vertebrates are evolved. On this hypothesis the discovery of the veins and of their relation to those of the pectoral and pelvic fins may be looked upon as an indirect

confirmation of the lateral fin theory. BALFOUR himself considered that, if they could be found in the embryo or in some less specialized form than the skate, their presence would furnish an argument in favour of the theory. In quoting this opinion of BALFOUR'S (22, p. 232) I have pointed out that the vein in question is now known to exist in at least four genera of Selachians, and that in an embryo of *Scymnus lichia*, corresponding very nearly with BALFOUR'S "Stage O" (1, Plate VIII., figs. 0, 0'; 22, Plate XXXII., fig. 13), it is a large and important trunk. Figs. 29-32 (Plate 37) show the relations of the lateral vein in various transverse sections of this embryo; from its conspicuous character one is rather surprised to find that BALFOUR makes no mention of it in any of the forms investigated by him. Mr. SEDGWICK, however, informs me that a re-examination of some of his sections has shown the vein to be present.

In the paper last referred to (22) I have also hazarded the suggestion that the lateral veins may be genetically connected with the lateral vessels of a vermian ancestor. As BALFOUR has shown, the dorsal aorta is the primary dorsal trunk of the vertebrata, the sub-intestinal vein their primary ventral trunk, the cardinal veins being quite secondary structures. I have, unfortunately, no Selachian embryos of an earlier stage than "O," and am therefore unable to say at what period the lateral vein makes its appearance, whether before or after the cardinals. If further investigation should show it to arise before the latter it will have to be definitely reckoned as one of the primary vascular trunks of the *Protochordata*; if shown to have a later origin its phylogenetic significance will be left still uncertain.

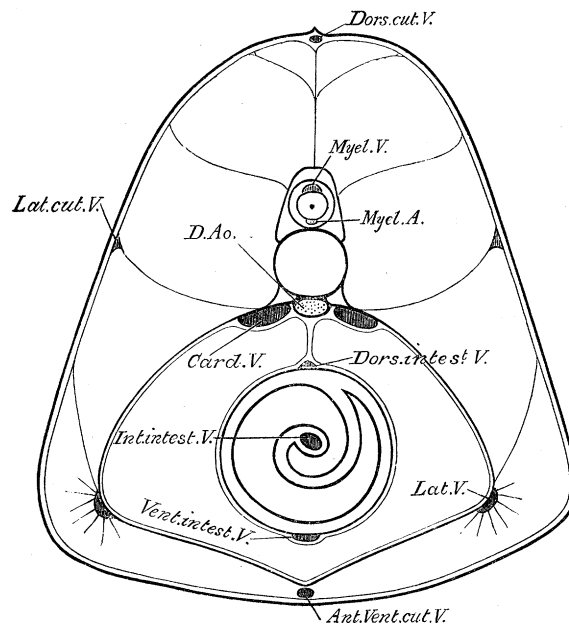
In any case there can be no doubt that the blood-vessels must not be left out of consideration in instituting comparisons between the Vertebrata and the lower types. For instance, according to HUBRECHT'S hypothesis (9), the Chordata are derived from Nemertean-like forms, in which the lateral nerve-cords have coalesced dorsad of the proboscidean sheath, which latter has been modified into the notochord. Comparing the vascular trunks of a Nemertean with those of an embryo Selachian, we find in both a dorsal and a pair of lateral vessels; the lacunæ described by OUDEMANS (18), in *Valencinia*, as lying symmetrically ventro-laterad of the proboscidean sheath may also, perhaps, be compared with the cardinal veins, but the ventral vessel, so characteristic of vertebrates, is wholly absent in the worm.

Again, if with DOHRN, SEMPER, and others, we compare a vertebrate with an inverted Annelid, we find certain interesting agreements between the blood-vessels of the two. In Chætopods there is a dorsal vessel in which the blood flows forwards (from tail to head), and which is intimately connected with the dorsal wall of the intestine. This, on the inverted Annelid theory, answers to the sub-intestinal vein of the Selachian embryo, in which the blood also flows forwards, and which arises in the splanchnopleure. The dorsal aorta would then correspond with the supra-neural vessel of the worm, and the lateral vessels of the two types would agree with one another; the myelonal vein of Selachians might also be compared with the sub-neural

vessel of some Annelids. Thus the study of the vascular system would seem to lend more support to the Annelid than to the Nemertean theory, a strong point against the latter hypothesis being the absence of a ventral vessel in any known Nemertean.

The most recent speculation of this sort is that of BATESON (3), who proposes to include *Balanoglossus* in the Chordate Phylum. This theory clearly receives no support from a comparison of the blood-vessels of the Enteropneusta with those of the Vertebrata. *Balanoglossus* certainly possesses dorsal, ventral, and lateral trunks, but the blood in the dorsal vessel—which, by the hypothesis, answers to the dorsal vessel of vertebrates—flows from behind forwards, and both dorsal vessel and heart lie dorsad of the supposed notochord.

Fig. A.



Diagrammatic transverse section of the trunk region of a Selachian, showing the principal longitudinal blood-vessels. The arteries are distinguished by dotting, the veins by vertical shading. (For explanation of reference letters see p. 726.)

The diagram, fig. A (woodcut), will probably be useful as showing the position of the chief longitudinal vessels—arteries and veins—in the trunk region of a typical Selachian. Of these the dorsal aorta and the intra-intestinal (sub-intestinal) vein are of primary importance in any phylogenetic speculations which avoid favouritism towards particular organs or sets of organs; the lateral veins are probably, and the cardinal veins certainly, sub-primary, while the remaining vessels, with the possible exception of the myelonal vein, are, in all probability, of altogether secondary significance.

D. *System of the Coronary Veins.*

7. *The Coronary Veins.*

There are two coronary veins in *Mustelus* (Plate 34, fig. 4, *Cor. V.*), a right and a left, situated one on either side of the furrow between the auricle and the ventricle. Each receives the veins from its own side of the ventricle and conus arteriosus, and, passing backwards, opens into the sinus venosus (fig. 9, *Cor. V'*) in the immediate neighbourhood of the sinu-auricular aperture (*Sin. aur. ap.*).

E. *System of the Cutaneous Veins.*

The cutaneous, like the lateral veins, were first described by ROBIN* as lymphatics. He, however, seems to have missed the dorsal and the posterior ventral cutaneous veins, and his researches, judging from the abstract of them given by MILNE EDWARDS, are imperfect in many particulars. As far as my experience goes the vessels in question invariably contain blood.

8. *The Dorsal Cutaneous Vein.*

This (Plate 36, figs. 14 and 15; Plate 37, figs. 22 and 24, *Dors. cut. V.*) is a median longitudinal vessel, imbedded in the dermis, and extending from the tail to some distance in front of the first dorsal fin.

Tracing it forwards from the tail, it is found to divide, immediately caudad of the second dorsal fin, into two vessels, which embrace the base of the fin, uniting again in front of it so as to form a complete loop (fig. 14, *d, f, 2*). On reaching the posterior border of the first dorsal fin (fig. 15) the dorsal cutaneous vein divides into three branches, one median and two paired; the latter (*d, f, 1*) extend forwards, one on each side of the base of the fin, and unite in front of it in an azygos subcutaneous trunk; the median branch leaves the skin, and passes downwards and forwards in the median fibrous septum dividing the muscles of the right and left sides (fig. 22); on reaching the vertebral column it turns to the left of the latter—in the single specimen in which it was traced out—and, continuing its downward course, opens into the left renal portal vein.

9. *The Anterior Ventral Cutaneous Vein.*

Tronc lymphatique médian abdominal, ROBIN, quoted by MILNE EDWARDS (15).

This vessel (Plate 36, fig. 14; Plate 37, figs. 21, 22, and 24, *Ant. vent. cut. V.*) lies in the middle ventral line of the abdomen, extending from the shoulder

* ROBIN, 'Revue Zoologique,' 1845.—Quoted by MILNE EDWARDS (15).

girdle in front to the pubis behind. It is situated mesiad of the skin, *i.e.*, between it and the abdominal muscles. It receives numerous tributaries which form a very beautiful plexus on the abdominal wall immediately beneath the skin. Anteriorly the vein trifurcates, the three branches uniting again in the form of a rhomboid, the lateral angles of which are connected with the lateral veins (fig. 14) close to the entrance of the brachial veins. Posteriorly the anterior ventral cutaneous vein sends off two branches, a right and a left, almost at right angles; these pass along the ventral aspect of the pubic cartilage, turn round the outer border of the latter, and then, passing inwards parallel to and dorsal of their former course, anastomose with the iliac veins (figs. 3 and 14).

10. *The Posterior Ventral Cutaneous Vein*

(Plate 34, fig. 3; Plate 36, fig. 14, *Post. vent. cut. V.*) lies in the middle ventral line of the caudal region. Passing forwards from the tail it forms a loop round the base of the ventral (so-called anal) fin (fig. 14, *V. f.*) like those formed round the dorsal fins by the dorsal cutaneous vein. Arriving at the hinder wall of the cloaca it bifurcates, the two branches anastomosing each with the corresponding cloacal vein.

There is thus direct communication, through the cloacal and iliac veins, between the anterior and posterior ventral cutaneous veins; indeed, they might almost be described as a single vessel forming loops round the anal fin and the cloaca. It will be noticed that there is a curious parallelism between these vessels and the sub-intestinal vein, which, in its early state of entirety, forms a loop round the cloaca.

11. *The Lateral Cutaneous Vein.*

Tronc lymphatique latéral sous-cutané, ROBIN, quoted by MILNE EDWARDS (15).

The lateral cutaneous veins (Plate 36, figs. 14 and 16; Plate 37, figs. 22 and 24, *Lat. cut. V.*) are paired longitudinal vessels, extending along the side of the trunk and tail at the junction of the dorsal and ventral muscles. Like the ventral cutaneous veins, they lie immediately beneath the skin. They anastomose posteriorly both with the caudal and with the dorsal cutaneous vein (fig. 14); anteriorly each discharges into the corresponding subscapular sinus (figs. 14 and 16).

GENERAL CONSIDERATIONS.

One of the most striking features of the blood-vessels of Selachians, as represented by *Mustelus antarcticus*, is the number of large anastomotic trunks between important arteries and veins. In the arteries there are commissures uniting the anterior and posterior carotids (Plate 35, fig. 6, *w*), others placing the efferent arteries of each

holobranch in communication (*com.* 2), and others uniting the whole series of efferent branchial arteries with the subclavians (Plate 34, fig. 2; and Plate 35, fig. 6, *com.* 1).

But it is in the venous system that we find the most striking cases of anastomosis. The hyoidean sinuses communicate with the jugulars, with the inferior jugulars, and with one another (Plate 34, fig. 2); the cardinals are placed in communication with one another (Plate 35, fig. 10) and with the portal vein (figs. 10 and 12); the lateral veins unite with one another (fig. 1), as also do the cloacal veins (Plate 36, fig. 14); the anterior ventral cutaneous vein opens in front into the lateral, behind into the iliac veins (fig. 14); the lateral cutaneous is connected with the subscapular vein in front and with the caudal and dorsal cutaneous veins behind.

The diagram, fig. B (woodcut), is intended to bring out these peculiarities of the venous system. There can be little doubt that, in many instances, alternative courses are open to the returning blood, so that the venous portion of the circulation is by no means so definite as in the higher animals.

Another point of interest is the tendency of the veins to enlarge into great irregular sinuses. The cardinals dilate anteriorly into capacious cardinal sinuses, and the hepatic veins into an immense hepatic sinus; the blood from the head is poured partly into the orbital, partly into the hyoidean sinuses. In fact the majority of the venous channels, as will be seen by an inspection of figs. 1 and 2, are of a calibre quite disproportionate to that of the corresponding arteries.

Thus the veins of a Selachian have more or less of a lacunar character, reminding one of what is found in many of the higher Invertebrata. It is a question how far this state of things is primary or ancestral, and how far secondary.

Other matters of general interest are discussed in earlier portions of the paper. The most important of these are: the relation of the arteries of the adult to the embryonic aortic arches (pp. 689-691); the renal portal system (pp. 704 and 714); the derivatives of the embryonic sub-intestinal vein (p. 709); the homology of the lateral vein with the epigastric vein of Amphibia (p. 717); and the relation of the blood-vessels of Selachians to the primary vascular trunks of the Chordata (p. 718).

METHODS OF INVESTIGATION.

The arteries may be conveniently injected from the ventral gastric artery, the cannula being directed towards the dorsal aorta; if the operation is conducted successfully the whole arterial system is filled, with the exception, of course, of the branches of the ventral gastric artery itself. Fine (dental) plaster of Paris coloured with vermilion or carmine forms an excellent injecting material.

The injection of the veins is more difficult. By injecting from the anterior lieno-gastric or from the dorsal intestinal vein, the cannula being directed towards the main portal vein, the whole of the portal system is filled, the injection usually also passing through the spermatico-portal anastomosis into the cardinals, sinus

venosus, and hepatic sinus. The renal portal veins may be separately injected from the caudal vein, in which case it is instructive to use a different colour to that employed for the cardinals. Owing to the extreme thinness of their walls a comparatively slight pressure is sufficient to rupture the renal portal veins.

The lateral veins may be injected by opening the abdomen, cutting across one of the veins and pushing a tapering glass cannula into it far enough to prevent escape; tying is inadmissible since the lateral veins cannot readily be dissected from the surrounding muscle. The cutaneous veins have to be separately filled in the same way. The jugular may be injected from the ventral end of the hyoidean sinus or from the precaval sinus by pushing the cannula beyond the valves.

For all the above methods of venous injection, plaster of Paris may be used as for the arteries, but for accurate investigations it is advisable to employ a solution of gelatine coloured with precipitated carmine or Prussian blue. The vessels, unlike those of Teleosts, will bear a moderately high temperature (40° - 50° C.) without injury.

The whole vascular system may be more or less successfully filled by injecting from any branch of the coeliaco-mesenteric artery with gelatine coloured with Prussian blue, and, when the mass has passed the capillaries and filled the veins, withdrawing the syringe and injecting immediately, through the same cannula, with plaster of Paris coloured with vermilion; this replaces the gelatine as far as the smallest arteries, but no farther, so that the arteries become filled with red and the veins with blue.* It is only by injecting in this way, so as to fill the veins from the capillaries, that I have ever succeeded in satisfactorily demonstrating the cerebral and myelonal veins.

A very instructive preparation of the splanchnic vessels may be made by injecting from the ventral gastric artery and anterior lieno-gastric vein with red and blue plaster of Paris respectively, then removing the alimentary canal, and, after washing out its contents, distending with air and drying. When dry the intestine should be opened in one or two places to show the spiral valve and the intra-intestinal artery and vein.

For making out the precise position of the chief vessels in relation to surrounding parts, as well as for settling many points left uncertain by ordinary dissection, sections of frozen specimens are extremely useful. I have prepared a complete series of transverse sections of an adult female, as well as horizontal and vertical longitudinal sections of the head and shoulders of other specimens. I have to thank Mr. W. Cunningham Smith, Secretary of the New Zealand Refrigerating Company, for allowing me to have my specimens frozen at the Company's works, Burnside, near Dunedin. I may mention that fishes are far more difficult to freeze than mammals; after six days' exposure to a temperature of 20° F. (about -7° C.), my dog-fishes, which were

* This method has been recommended by my friend Prof. H. F. Osborn, of Princeton ('American Naturalist,' vol. 19, 1885, p. 526, and 'Microsc. Soc. Journ.,' vol. 5, 1885, p. 905).

not more than 3 feet long and 5 inches in diameter, were less thoroughly frozen than the carcasses of sheep exposed to the same temperature for forty-eight hours.

BIBLIOGRAPHY.

The following list contains only the names of such works as I have myself been able to consult; one or two papers quoted at second-hand are referred to in foot-notes.

1. BALFOUR, F. M. 'A Monograph on the Development of Elasmobranch Fishes.' London, 1878.
2. BALFOUR, F. M. 'A Treatise of Comparative Embryology.' Vol. 2. London, 1881.
3. BATESON, W. "The Later Stages in the Development of *Balanoglossus Kowalevskii*, with a suggestion as to the Affinities of the Enteropneusta." 'Quart. Journ. Microsc. Sci.,' vol. 25, 1885 (Suppl.), p. 81.
4. CLAUS, C. 'Text-book of Zoology.' (English Edition.) Vol. 2. London, 1884.
5. DOHRN, A. "Die Entwicklung und Differenzirung der Kiemenbogen der Selschier." 'Neapel, Zool. Stat. Mittheil.,' vol. 5, 1884, p. 102.
6. DUVERNOY, G. L. "Sur quelques particularités du Système sanguin abdominal et du Canal alimentaire de plusieurs Poissons cartilagineux." (1833.) 'Ann. Sci. Nat., Zool.,' vol. 3, 1835, p. 274.
7. GEGENBAUR, C. 'Elements of Comparative Anatomy.' (English Edition.) London, 1878.
8. GÜNTHER, A. 'An Introduction to the Study of Fishes.' Edinburgh, 1880.
9. HUBRECHT, A. A. W. "On the Ancestral Form of the Chordata." 'Quart. Journ. Microsc. Sci.,' vol. 23, 1883, p. 349.
10. HUXLEY, T. H. 'A Manual of the Anatomy of Vertebrate Animals.' London, 1871.
11. HYRTL, J. "Das arterielle Gefäss-System der Rochen." 'Wien, Sitz. Ber.,' vol. 25, 1857, p. 236.
12. JOURDAIN, S. "Recherches sur la Veine Porte Rénale." 'Ann. Sci. Nat., Zool.,' vol. 12, 1859, p. 321.
13. MACALISTER, A. 'An Introduction to the Systematic Zoology and Morphology of Vertebrate Animals.' Dublin and London, 1878.
14. MILNE EDWARDS, H. 'Leçons sur la Physiologie et l'Anatomie Comparée,' vol. 3, 1858.
15. MILNE EDWARDS, H. *Op. cit.*, vol. 4, 1859.
16. MONRO, A. (Jun.) 'The Structure and Physiology of Fishes.' Edinburgh, 1785.
17. MÜLLER, J. 'Vergleichende Anatomie der Myxinoiden.' (1839.) Berlin, 1841.

18. OUDEMANS, A. C. "The Circulatory and Nephridial Apparatus of the Nemertea." 'Quart. Journ. Microsc. Sci.', vol. 25, 1885 (Suppl.), p. 1.
19. OWEN, R. 'On the Anatomy of Vertebrates.' Vol. 1. London, 1866.
20. PARKER, T. J. "On the Intestinal Spiral Valve in the genus *Raia*." (1879.) 'Zool. Soc. Trans.', vol. 11, p. 49.
21. PARKER, T. J. "On the Venous System of the Skate." 'New Zealand Instit. Trans.', vol. 13, 1881, p. 413.
22. PARKER, T. J. "Notes on the Anatomy and Embryology of *Scymnus lichia*." (1882.) 'New Zealand Instit. Trans.', vol. 15, 1883, p. 222.
23. PARKER, T. J. 'A Course of Instruction in Zootomy (Vertebrata).' London, 1884.
24. ROLLESTON, G. 'Forms of Animal Life.' Oxford, 1870.
25. STANNIUS, H. 'Handbuch der Anatomie der Wirbelthiere.' Berlin, 1846.
26. WIEDERSHEIM, R. 'Lehrbuch der vergleichenden Anatomie der Wirbelthiere.' Jena, 1883.

DESCRIPTION OF PLATES.

The Heart, Ventral Aorta, and Afferent Branchial Arteries are coloured *purple*, the remaining arteries *red*, and the veins *blue*; cartilaginous structures are *dotted*.

REFERENCE LETTERS.

The following list refers only to the vascular system; other structures are referred to in the description of the figures in which they occur:—

The letter *R* or *L* prefixed to an abbreviation indicates *right* or *left*.

When there is a series of vessels to which the same name is applied (*e.g.*, the afferent and efferent branchial arteries), the individual trunks are numbered from before backwards.

The aperture of an artery or vein into a vessel of higher order is indicated by the abbreviation for the vessel in question with the addition of a *dash*—*e.g.*, *Jug. v'*. in fig. 2 points to the aperture of the jugular vein into the precaval sinus.

Heart.

<p><i>Aur.</i> Auricle.</p> <p><i>C. art.</i> Conus arteriosus.</p>		<p><i>Sin. ven.</i> Sinus venosus.</p> <p><i>Sin. aur. ap.</i> Sinu-auricular aperture.</p>
<p><i>Vent.</i> Ventricle.</p>		

Arteries.

<i>Add. mand.</i>	Branch of mandibular to M. adductor mandibulæ.	<i>Inf. rect.</i>	Branch of orbital to M. rectus inferior.
<i>Af. br. A.</i>	Afferent branchial.	<i>Int. intest. A.</i>	Intra-intestinal.
<i>Ant. car. A.</i>	Anterior carotid.	<i>Int. rect.</i>	Branch of orbital to M. rectus internus.
<i>Ant. cerebr. A.</i>	Anterior cerebral.	<i>Mandib. A.</i>	Mandibular.
<i>Ant. gast. A.</i>	Anterior gastric.	<i>Max. na. A.</i>	Maxillo-nasal.
<i>Ant. lat. A.</i>	Anterior lateral.	<i>Myel. A.</i>	Myelonal.
<i>Ant. mes. A.</i>	Anterior mesenteric.	<i>Nu. br. A.</i>	Nutrient branchial.
<i>Ant. sperm. mes. A.</i>	Anterior spermatico-mesenteric.	<i>Nu. hy. A.</i>	Nutrient hyoidean.
<i>Brach. A.</i>	Brachial.	<i>Ophth. A.</i>	Ophthalmic.
<i>Buc. A.</i>	Buccal.	<i>Orbit. A.</i>	Orbital.
<i>Caud. A.</i>	Caudal.	<i>Ovid. A.</i>	Oviducal.
<i>Cereb. A.</i>	Cerebral.	<i>P. card. A.</i>	Pericardial.
<i>Cæl. A.</i>	Cœliac.	<i>Post. car. A.</i>	Posterior carotid.
<i>Cæl. mes. A.</i>	Cœliaco-mesenteric.	<i>Post. cerebr. A.</i>	Posterior cerebral.
<i>Com. 1.</i>	Commissural trunk uniting ventral ends of efferent branchials.	<i>Post. lat. A.</i>	Posterior lateral.
<i>Com. 2.</i>	Commissure uniting the two efferent branchials of each holobranch.	<i>Post. mes. A.</i>	Posterior mesenteric.
<i>Com. 3 and 4.</i>	Commissures uniting <i>com.</i> 1 with hypobranchials.	<i>Post. sperm. mes. A.</i>	Posterior spermatico-mesenteric.
<i>Cor. A.</i>	Coronary.	<i>Psbr.</i>	Arterioles of pseudobranch.
<i>Cor. mand.</i>	Branch of mandibular to M. coraco-mandibularis.	<i>Psbr. A.</i>	Pseudobranchial.
<i>D. Ao.</i>	Dorsal aorta.	<i>Pyl. A.</i>	Pyloric.
<i>Dors. gast. A.</i>	Dorsal gastric.	<i>Rost. A.</i>	Rostral.
<i>Dors. intest. A.</i>	Dorsal intestinal.	<i>Spl. A.</i>	Splenic.
<i>Ef. br. A.</i>	Efferent branchial.	<i>Subcl. A.</i>	Subclavian.
<i>Epbr. A.</i>	Epibranchial.	<i>Sup. obl.</i>	Branch of orbital to M. obliquus superior.
<i>Ext. rect.</i>	Branch of orbital to M. rectus externus.	<i>Sup. rect.</i>	Do. to M. rectus superior.
<i>Fem. A.</i>	Femoral.	<i>V. Ao.</i>	Ventral aorta.
<i>Hep. A.</i>	Hepatic.	<i>Vent. gast. A.</i>	Ventral gastric.
<i>Hypbr. A.</i>	Hypobranchial.	<i>Vent. intest. A.</i>	Ventral intestinal.
<i>Il. A.</i>	Iliac.	<i>w.</i>	Commissural trunk between anterior and posterior carotid.
<i>Inf. Obl.</i>	Branch of orbital to M. obliquus inferior.	<i>x.</i>	Point of origin of <i>y</i> from posterior carotid.
		<i>y.</i>	Hyoidean epibranchial.
		<i>z.</i>	Anterior or inter-hyoidean portion of dorsal aorta.

Veins and Sinuses.

<i>Ant. cerebr. V.</i>	Anterior cerebral.	<i>Il. V.</i>	Iliac.
<i>Ant. fac. V.</i>	Anterior facial.	<i>Inf. jug. V.</i>	Inferior jugular.
<i>Ant. gast. V.</i>	Anterior gastric.	<i>Int. intest. V.</i>	Intra-intestinal.
<i>Ant. li.-gast. V.</i>	Anterior lieno-gastric.	<i>Jug. V.</i>	Jugular.
<i>Ant. vent. cut. V.</i>	Anterior ventral cutaneous.	<i>Lat. cut. V.</i>	Lateral cutaneous.
<i>A.p.</i>	Aperture between right and left cardinals.	<i>Lat. V.</i>	Lateral.
<i>Brach. V.</i>	Brachial.	<i>Nu. br. V.</i>	Nutrient branchial.
<i>Card. S.</i>	} Cardinal.	<i>Nu. hy. V.</i>	Nutrient hyoidean.
<i>Card. V.</i>		<i>Orbit. S.</i>	Orbital.
<i>Caud. V.</i>	Caudal.	<i>Pancr. V.</i>	Pancreatic.
<i>Clo. V.</i>	Cloacal.	<i>Post. cerebr. V.</i>	Posterior cerebral.
<i>Cor. V.</i>	Coronary.	<i>Post. fac. V.</i>	Posterior facial.
<i>D. f. 1.</i>	Loop formed round base of 1st dorsal fin by dorsal cutaneous.	<i>Post. li.-gast. V.</i>	Posterior lieno-gastric.
<i>D. f. 2.</i>	Do. round 2nd dorsal fin.	<i>Post. vent. cut. V.</i>	Posterior ventral cutaneous.
<i>Dors. cut. V.</i>	Dorsal cutaneous.	<i>Pr. cav. S.</i>	Precaval.
<i>Dors. intest. V.</i>	Dorsal intestinal.	<i>S. scap. S.</i>	Subscapular.
<i>Duod. V.</i>	Duodenal.	<i>V.</i>	Anastomotic trunk between portal and spermatic.
<i>Fem. V.</i>	Femoral.	<i>V. f.</i>	Loop formed round base of ventral (=anal) fin by posterior ventral cutaneous.
<i>Gast. intest. V.</i>	Gastro-intestinal.	<i>Vent. gast. V.</i>	Ventral gastric.
<i>Hep. port. V.</i>	Hepatic portal.	<i>Vent. intest. V.</i>	Ventral intestinal.
<i>Hep. S.</i>	} Hepatic.		
<i>Hep. V.</i>			
<i>Hyoide. S.</i>	Hyoidean.		

PLATE 34.

Mustelus antarcticus.

Fig. 1. General view of the vascular system from the ventral aspect (half nat. size).

The afferent branchial arteries are removed on the left side (right in the figure) and the greater part of the efferent branchials on the right; the left efferent branchials have their ventral ends reflected outwards so as to bring them into one plane.

Fig. 2. The heart with the chief arteries and veins of the sub-mental and sub-branchial regions; from the ventral aspect (nat. size).

The arteries are for the most part removed on the right side (left in the

figure) and the veins on the left ; the precaval sinus has its ventral wall removed.

Fig. 3. The vessels in connexion with the cloaca and adjacent parts ; from the left side (nat. size).

Clo., cloaca ; *Kd.*, left kidney ; *Rect.*, rectum ; *Rect. gl.*, rectal gland ; *Ov.*, ovary ; *Ovd.*, left oviduct.

Fig. 4. The heart ; from the right side (nat. size).

Fig. 5. Transverse section of the second holobranch (nat. size).

Br. fil., branchial filaments ; *Br. r.*, cartilaginous branchial ray ; *C. br.*, cerato-branchial ; *Ex. br.*, extra-branchial ; *M. ep. c. br.*, M. epi-cerato-branchialis ; *M. rad.*, radiating muscle ; *No. 1*, *No. 2*, branches of vagus.

PLATE 35.

Mustelus antarcticus.

Fig. 6. The anterior portion of the dorsal aorta with the efferent branchial, cephalic, &c., arteries ; from the ventral aspect (nat. size).

The efferent branchial arteries are brought into one plane by their ventral ends being reflected outwards.

Fig. 7. The coeliaco-mesenteric artery ; from the ventral aspect (nat. size).

Fig. 8. The brain and anterior part of the spinal cord, showing the arteries on the left side, the veins on the right ; from the dorsal aspect (nat. size).

Dien., diencephalon (=thalamencephalon) ; *Epen.*, epencephalon or cerebellum ; *Mesen.*, mesencephalon (optic lobes) ; *Meten.*, metencephalon or medulla oblongata ; *Myel.*, myelon or spinal cord ; *Prosen.*, prosencephalon ; *Rhinen.*, rhinencephalon or olfactory lobe.

Fig. 9. Part of a longitudinal horizontal section of a frozen specimen, showing the connexion of the chief veins with the sinus venosus and precaval sinus ; seen from the dorsal aspect (nat. size).

Lr., liver ; *p.*, partition dividing hepatic sinus into right and left compartments ; *Peric. perit. Sept.*, pericardio-peritoneal septum.

Fig. 10. Diagrammatic view of the head with the chief blood-vessels ; from the left side (nat. size).

Aud. caps., auditory capsule ; *C. br. 5*, dorsal end of fifth cerato-branchial ; *C. hy.*, dorsal end of cerato-hyal ; *Ep. br. 5*, ventral end of fifth epi-branchial ; *Hy. Mn.*, ventral end of hyomandibular ; *Mck.*, proximal end of lower jaw ; *Pl. Qu.*, proximal end of upper jaw ; *Spir.*, spiracle.

Fig. 11. The left orbital artery, showing the branches to the eye muscles (nat. size).

PLATE 36.

Mustelus antarcticus.

Fig. 12. The alimentary canal and its blood-vessels; from the dorsal aspect (half nat. size).

Card. st., cardiac division of stomach; *Pyl. st.*, pyloric division; *Intest.*, intestine, partly cut open to show *Spir. V.*, spiral valve; *Rect.*, rectum; *Rect. gl.*, rectal gland.

Fig. 13. The hepatic portal vein; from the ventral aspect (nat. size).

Fig. 14. The cutaneous veins; from the ventral aspect (half nat. size).

All four veins are shown as interrupted a short distance caudad of the vent, so as to bring them within the compass of the plate; the dorsal vein is also interrupted, for the sake of clearness, where it passes behind the cloacal, &c., veins.

Fig. 15. The first dorsal fin and adjacent parts, showing the relation of the dorsal cutaneous vein to the fin and to the renal portal vein; from the left side (half nat. size).

Kd., the left kidney.

Fig. 16. The left subscapular sinus, supposed to be seen through the scapula, showing the entrance of the lateral cutaneous vein; from the left side (nat. size).

Scap., scapula.

Callorhynchus antarcticus.

Fig. 17. The efferent branchial and cephalic arteries with part of the dorsal aorta, for comparison with fig. 6; from the ventral aspect (nat. size).

PLATE 37.

Mustelus antarcticus.

Transverse sections of adult female (all $\frac{2}{3}$ nat. size).

Fig. 18. Through the branchial region; posterior face of section.

Br. 1, *Br. 2*, first and second holobranchs; *Hy.*, hyoidean hemibranch; *Ph.*, pharynx.

Fig. 19. Taken immediately caudad of the dorsal moiety of the pericardio-peritoneal septum and through the posterior extremity or apex of the ventricle; on the right side the pericardio-peritoneal septum is cut away and the sinus venosus and precaval sinus are opened; posterior face of section.

Cor., coracoid; *Æs.*, œsophagus; *Peric. perit. Sept.*, pericardio-peritoneal septum.

- Fig. 20. Anterior face of the next section, showing the apex of the ventricle and the ventral moiety of the pericardio-peritoneal septum.
The anterior end of the liver (*Lr.*) is cut through, showing the hepatic sinus with its vertical partition (*P.*). In the cardinal sinus is seen the aperture of the subscapular sinus (*S. scap. S'*), and the lateral vein is cut through close to the entrance of the brachial vein (*Brach. V'*); *Cor.*, coracoid; *Ovd.*, oviduct.
- Fig. 21. Posterior face of the same section, showing the cardinal sinuses at their widest. Letters as before.
- Fig. 22. Through the first dorsal fin, showing the principal abdominal viscera and their blood-vessels; posterior face of section.
Card. st., cardiac division of stomach; *Pyl. st.*, pyloric division; *Intest.*, intestine showing spiral valve; *Lr.*, liver; *Spl.*, spleen; *Ov.*, ovary; *Ovd.*, oviducts, the left abnormally situated to the right of the stomach and intestine; *Kd.*, kidneys.
- Fig. 23. Portion of section through the posterior abdominal region (4 cms. cephalad of pubes), showing the median position of the right cardinal.
- Fig. 24. Through the symphysis pubis, showing the diminished size of the cardinal, the increased size of the renal portal, and the anastomosis of the lateral veins; anterior face of section.
Rect., rectum; *Ovd.*, oviducts.
- Fig. 25. Posterior face of part of the same section, showing the caudal vein bifurcating to form the renal portals.

Scymnus lichia.

Transverse sections of embryo, "Stage O" (BALFOUR); all fifteen times nat. size.

- Fig. 26. Through the posterior branchial region. Various segments of the branchial arches, not yet chondrified, are indicated by dark shading.
Br. 2, Br. 3, the second and third holobranchs; *Ph.*, the pharynx.
- Fig. 27. Through the cardiac region. The section is slightly oblique, the right side being caudad of the left, and showing the entrance of the jugular into the precaval sinus; on the left side the jugular and inferior jugular are still separate.
Æs., œsophagus.
- Fig. 28. Taken a short distance (eight sections) caudad of the preceding, which it resembles in being slightly oblique. On the left side the entrance of the cardinal into the precaval sinus is shown; on the right the cardinal is separate, and the entrance of the lateral vein is shown. The ventricle is

cut through immediately caudad of the auriculo-ventricular and arterial apertures.

Scap., scapula ; *Cor.*, coracoid.

Fig. 29. Through the pectoral fins.

St., stomach ; *Lr.*, liver ; *Ovd.*, oviduct ; *Som. stk.*, somatic stalk.

Fig. 30. Through the middle abdominal region.

Intest., intestine, with spiral valve ; *Spl.*, spleen ; *Ov.*, ovary ; other letters as before.

Fig. 31. Through the posterior abdominal region. The cardinal veins have united with one another immediately cephalad of their union with the caudal vein

Int. ren., inter-renal body ; other letters as before.

Fig. 32. Through the pelvic fins.

Rect., rectum ; *Rect. gl.*, rectal gland.

Parker.

Rost. A.

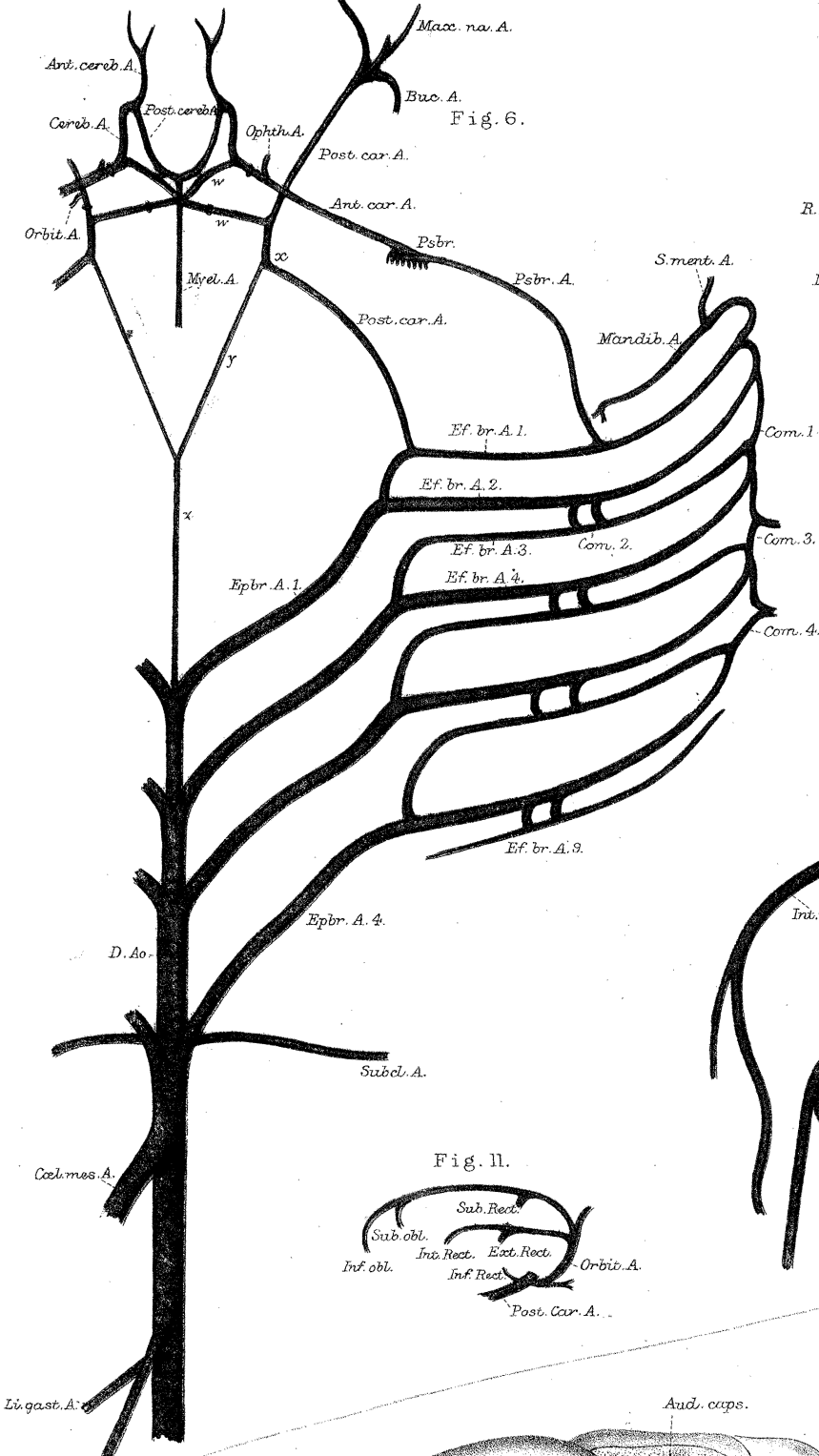


Fig. 6.

Phil.

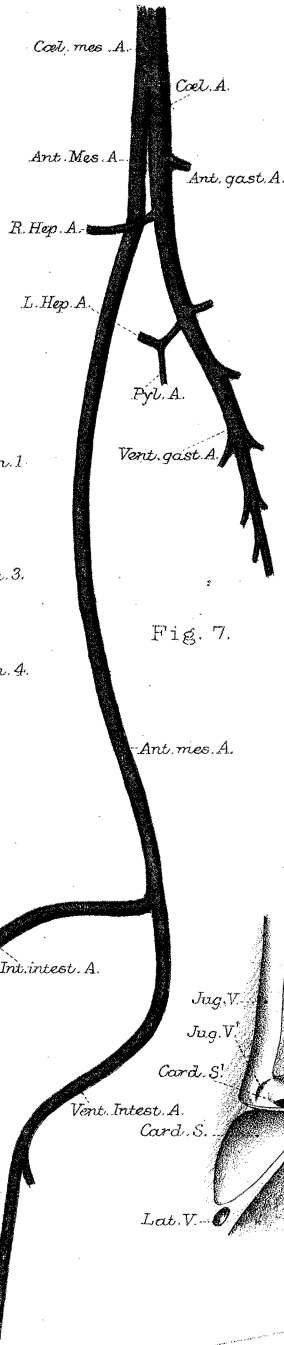
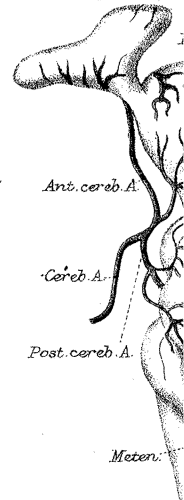


Fig. 7.



Myel.

Fig. 11.

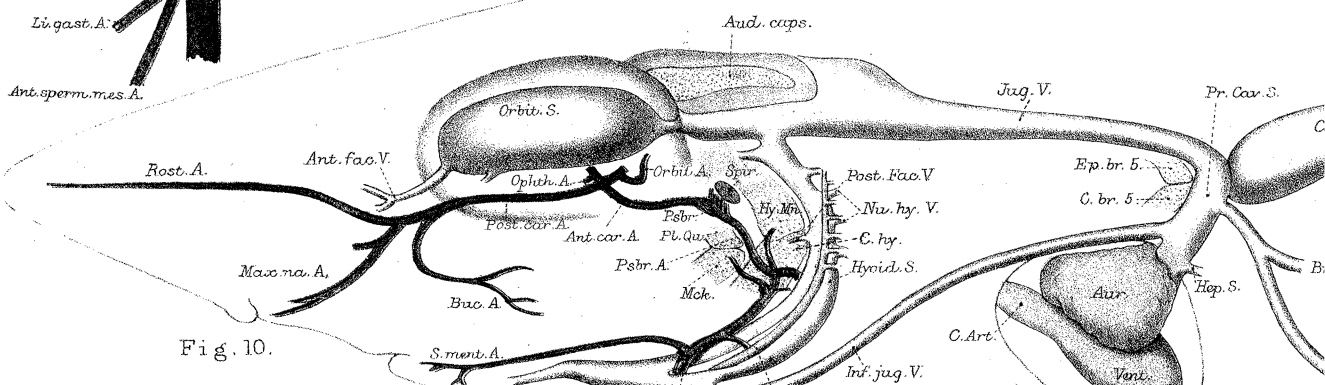
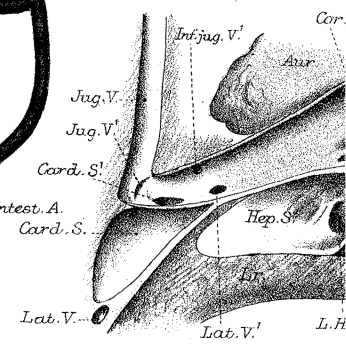



Fig. 10.

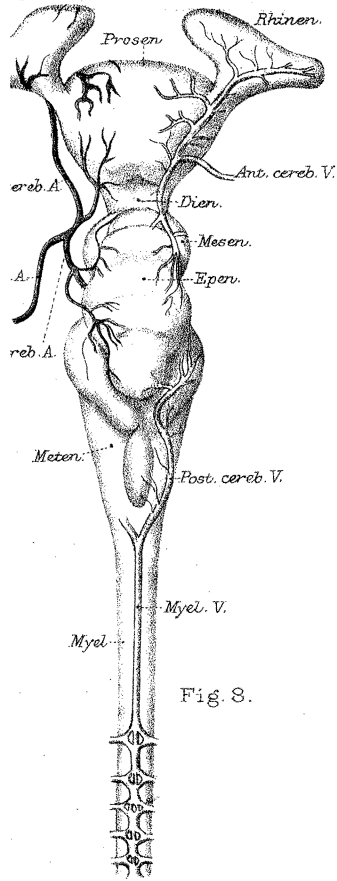


Fig. 8.

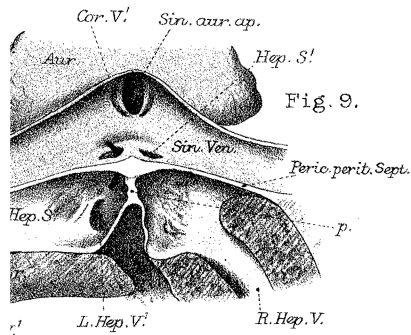
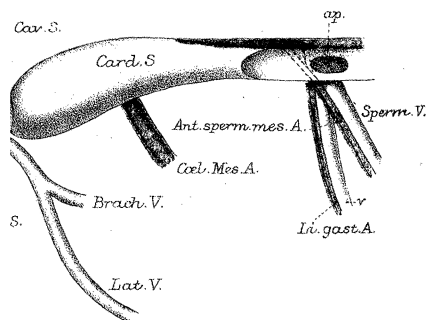


Fig. 9.



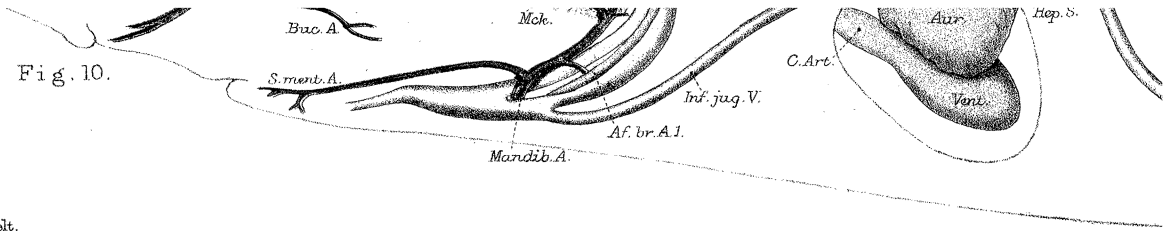


Fig. 10.

T.J.P. ad.nat. dolt.

Mustelus antarcticus.

S.



Lat. gast. A.

West, Newman & Co. imp.

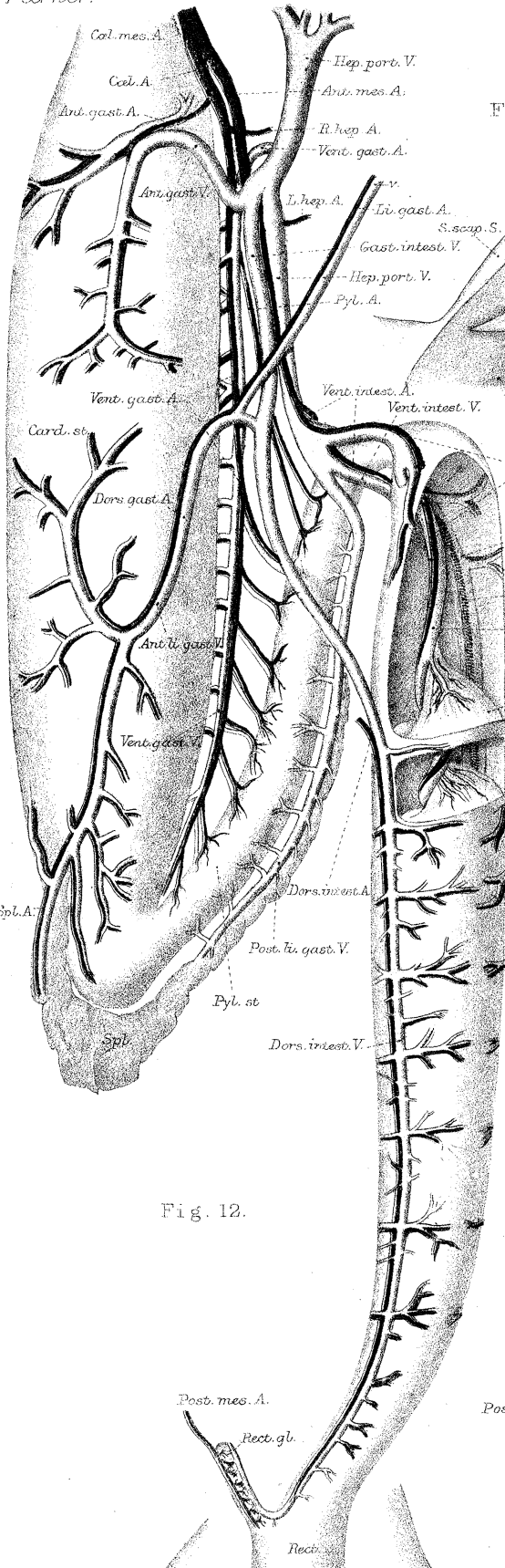


Fig. 12.

Fig. 15.

Fig. 16.


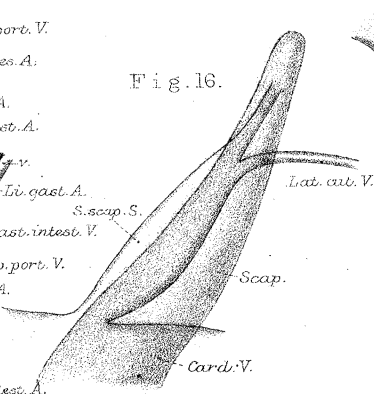


Fig. 13.

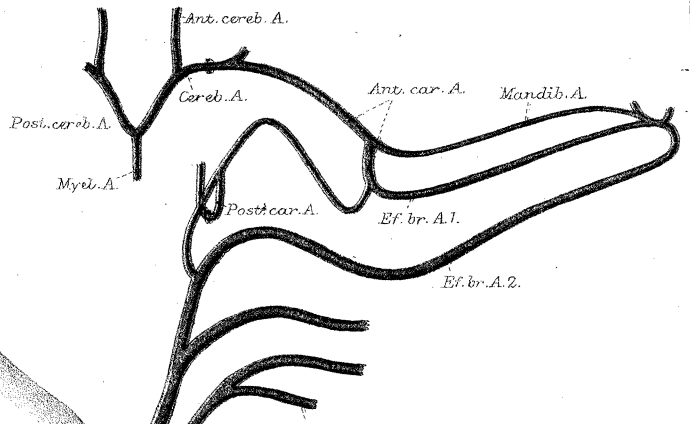
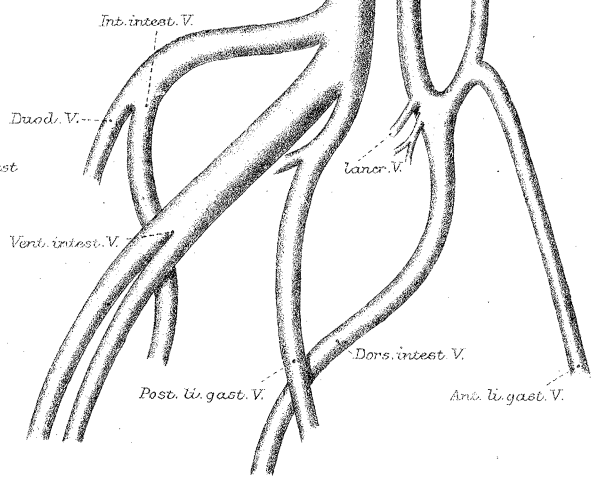
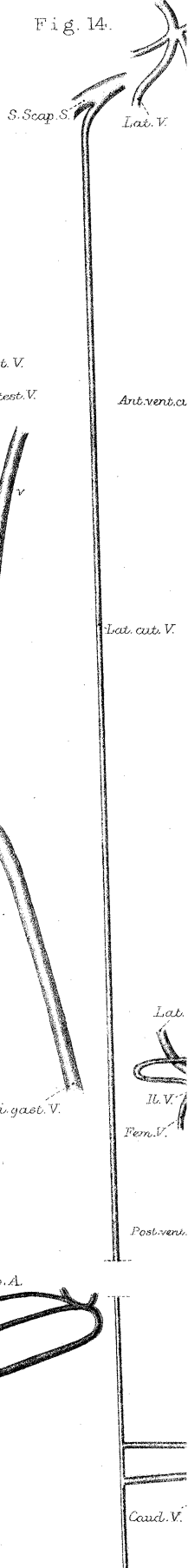
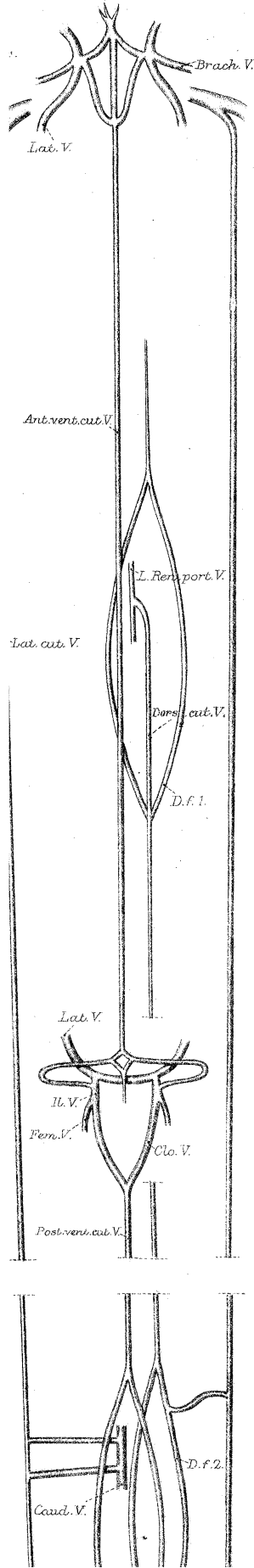
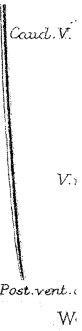
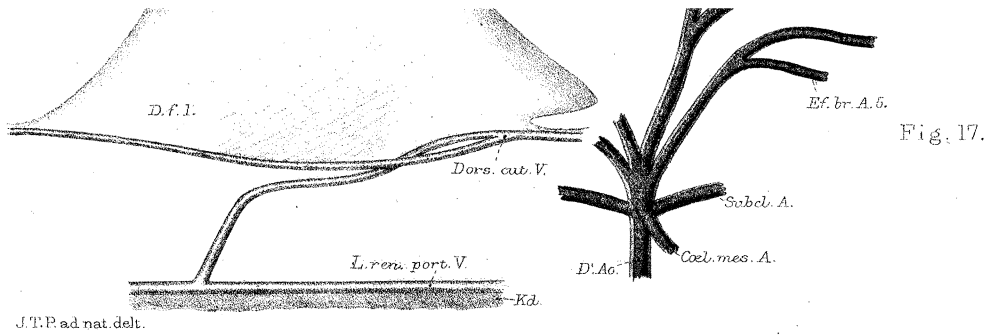


Fig. 14.

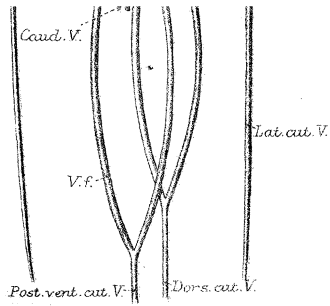




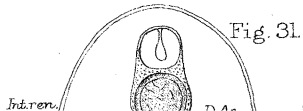

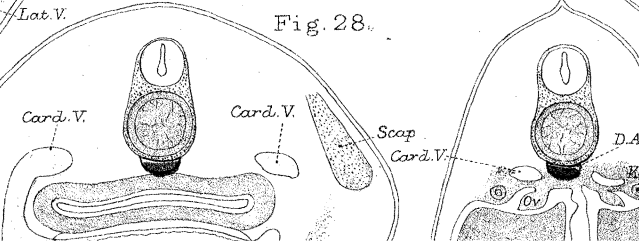
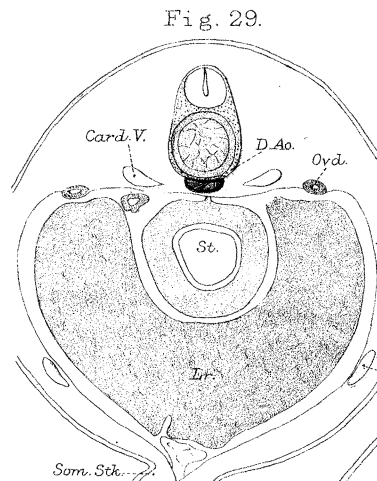
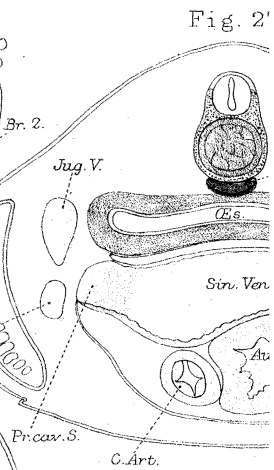
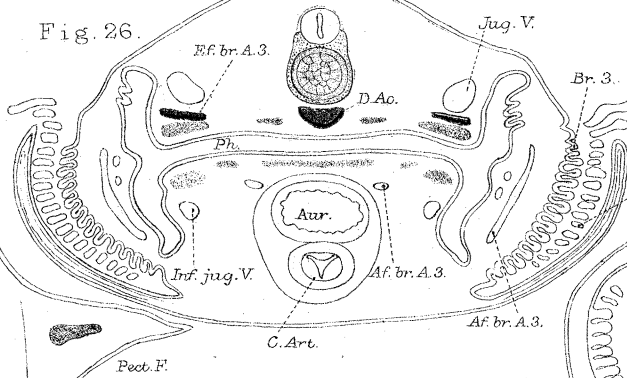
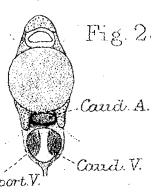
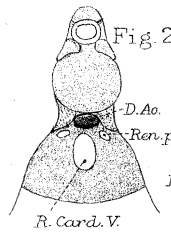
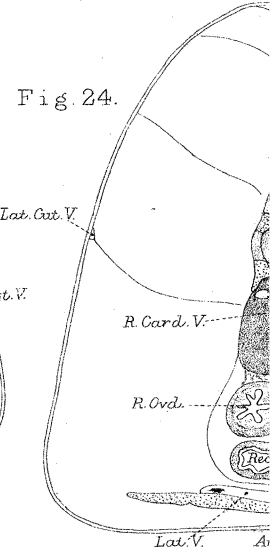
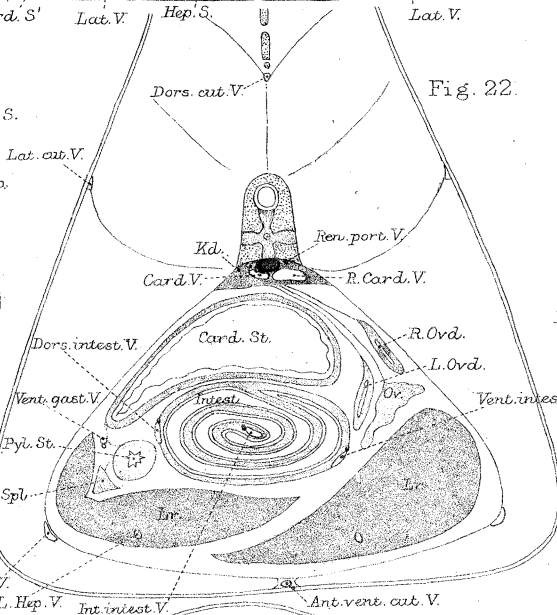
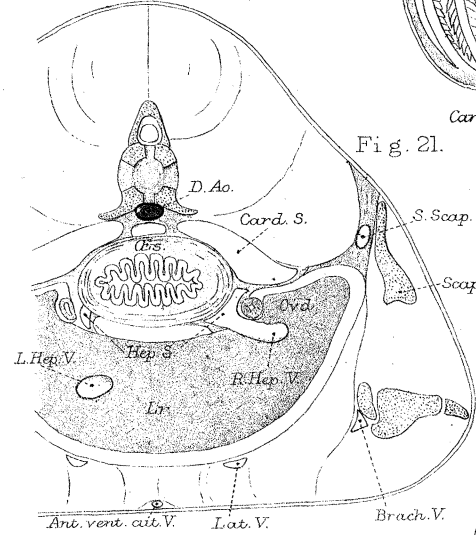
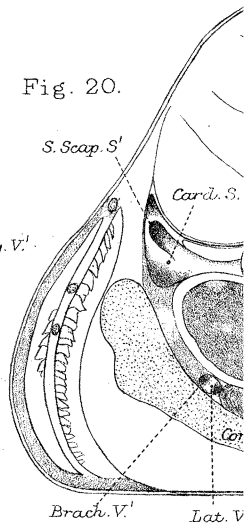
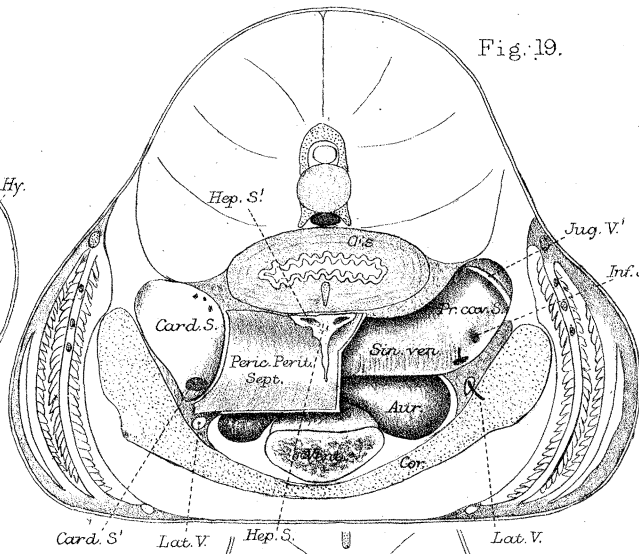
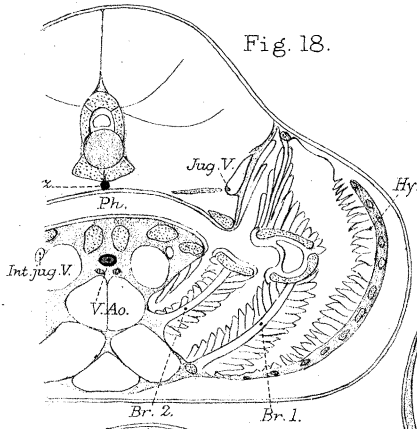


Figs. 12. 16, *Mustelus antarcticus*: Fig. 17, *Callorhynchus antarcticus*.

J.T.P. ad nat. del.



West, Newman & C^o imp.



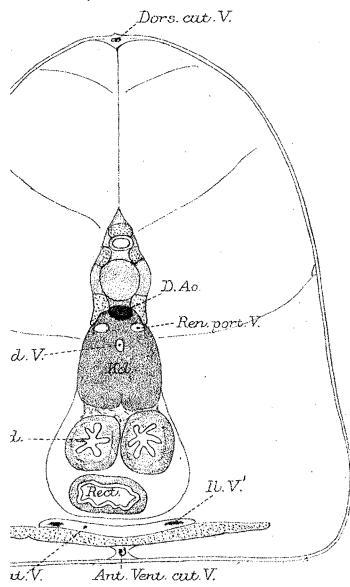
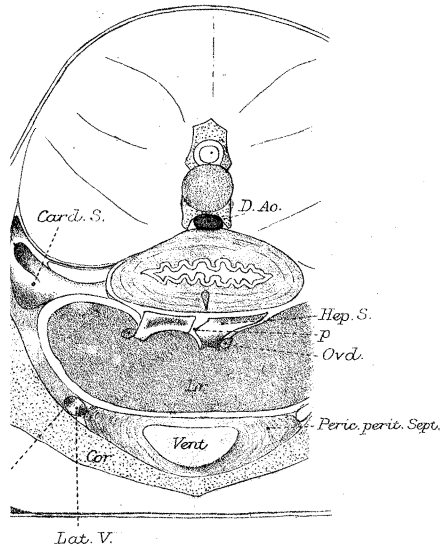


Fig. 27.

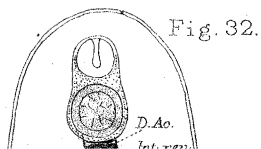
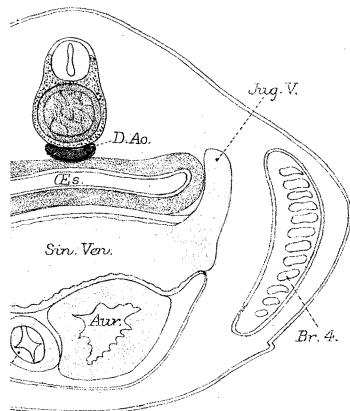
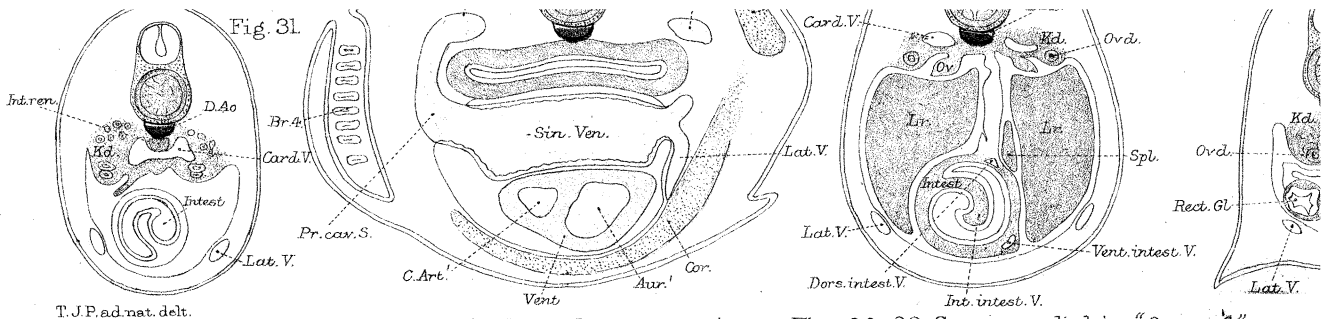
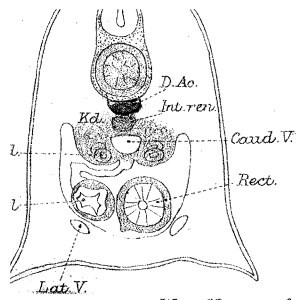


Fig. 32.



T. J. P. ad. nat. del.

Figs. 18-25, *Mustelus antarcticus*: Figs. 26-32, *Scymnus lichia*, "Stage 1"



West, Newman & C^o imp.

1''

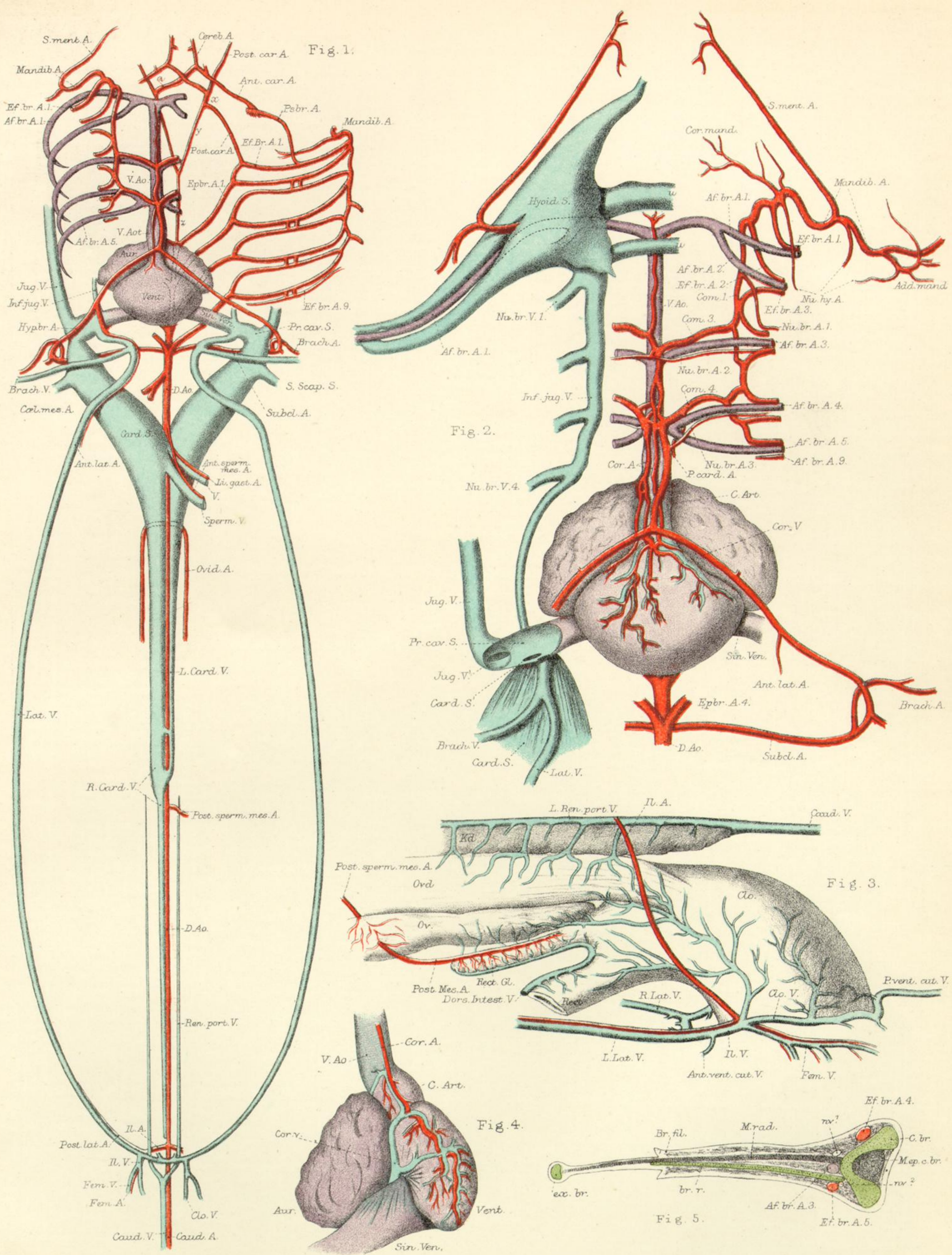


PLATE 34.

Mustelus antarcticus.

Fig. 1. General view of the vascular system from the ventral aspect (half nat. size).

The afferent branchial arteries are removed on the left side (right in the figure) and the greater part of the efferent branchials on the right; the left efferent branchials have their ventral ends reflected outwards so as to bring them into one plane.

Fig. 2. The heart with the chief arteries and veins of the sub-mental and sub-branchial regions; from the ventral aspect (nat. size).

The arteries are for the most part removed on the right side (left in the figure) and the veins on the left; the precaval sinus has its ventral wall removed.

Fig. 3. The vessels in connexion with the cloaca and adjacent parts; from the left side (nat. size).

Clo., cloaca; *Kd.*, left kidney; *Rect.*, rectum; *Rect. gl.*, rectal gland; *Ov.*, ovary; *Ovd.*, left oviduct.

Fig. 4. The heart; from the right side (nat. size).

Fig. 5. Transverse section of the second holobranch (nat. size).

Br. fil., branchial filaments; *Br. r.*, cartilaginous branchial ray; *C. br.*, cerato-branchial; *Ex. br.*, extra-branchial; *M. ep. c. br.*, M. epi-cerato-branchialis; *M. rad.*, radiating muscle; *No. 1*, *No. 2*, branches of vagus.

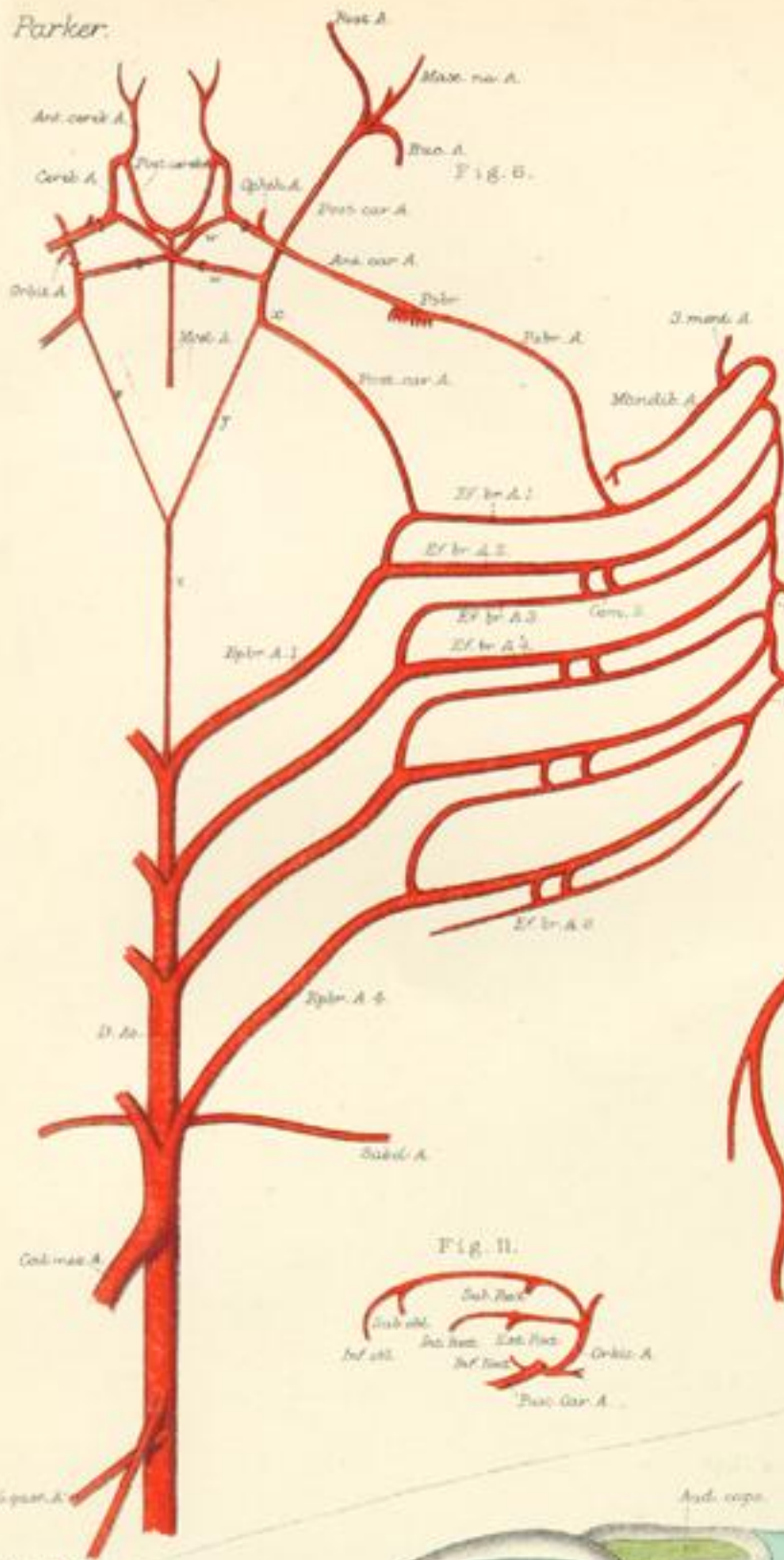


Fig. 6.

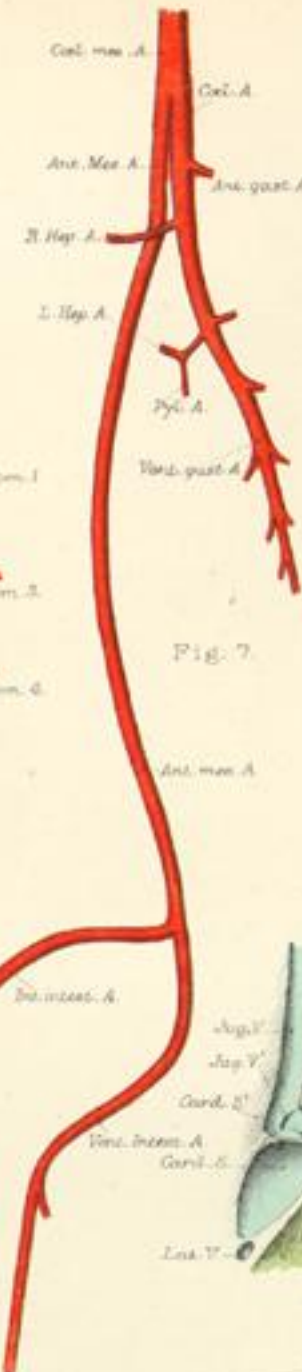

Fig. 7.

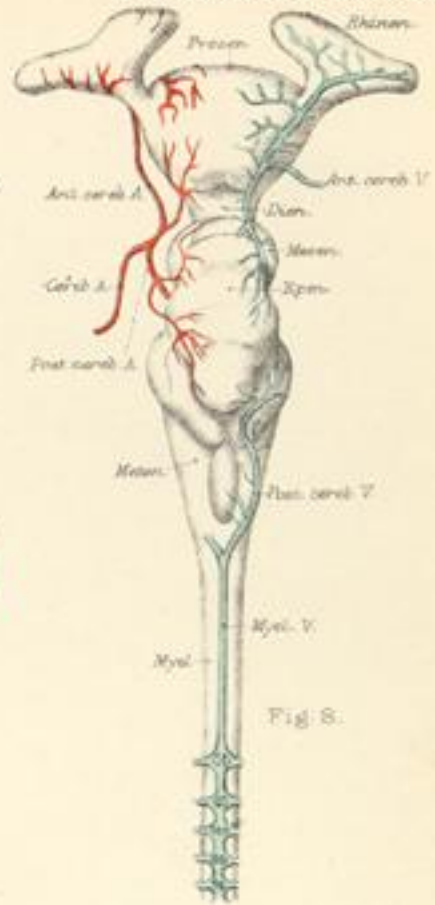


Fig. 8.

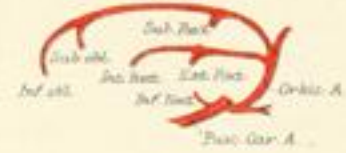

Fig. 11.

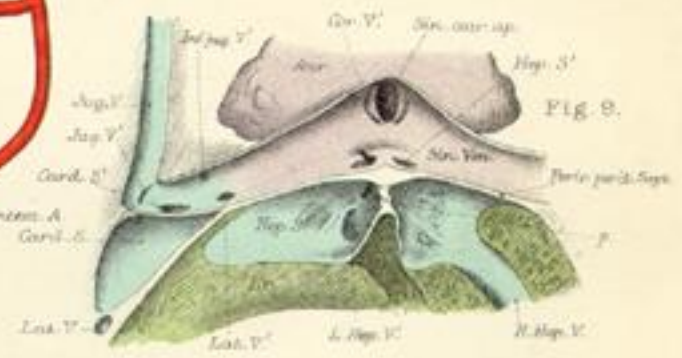


Fig. 9.

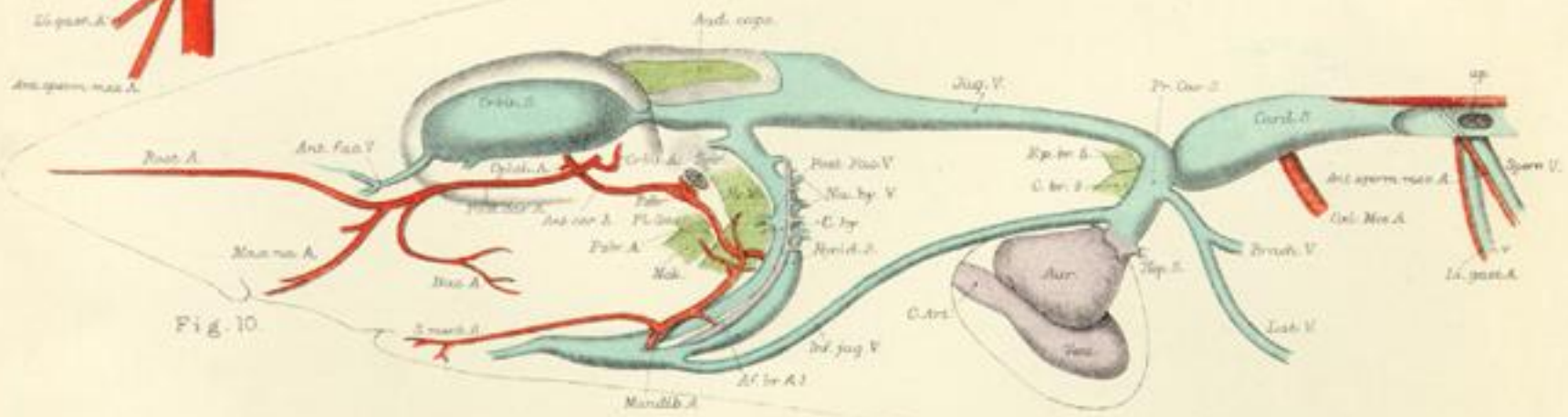


Fig. 10.

Parker.

Phil.

Fig. 6.

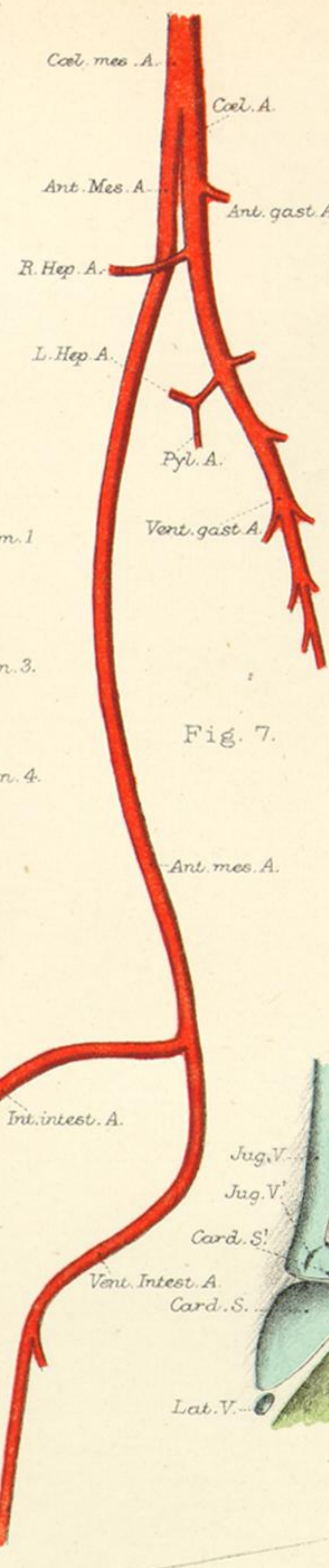
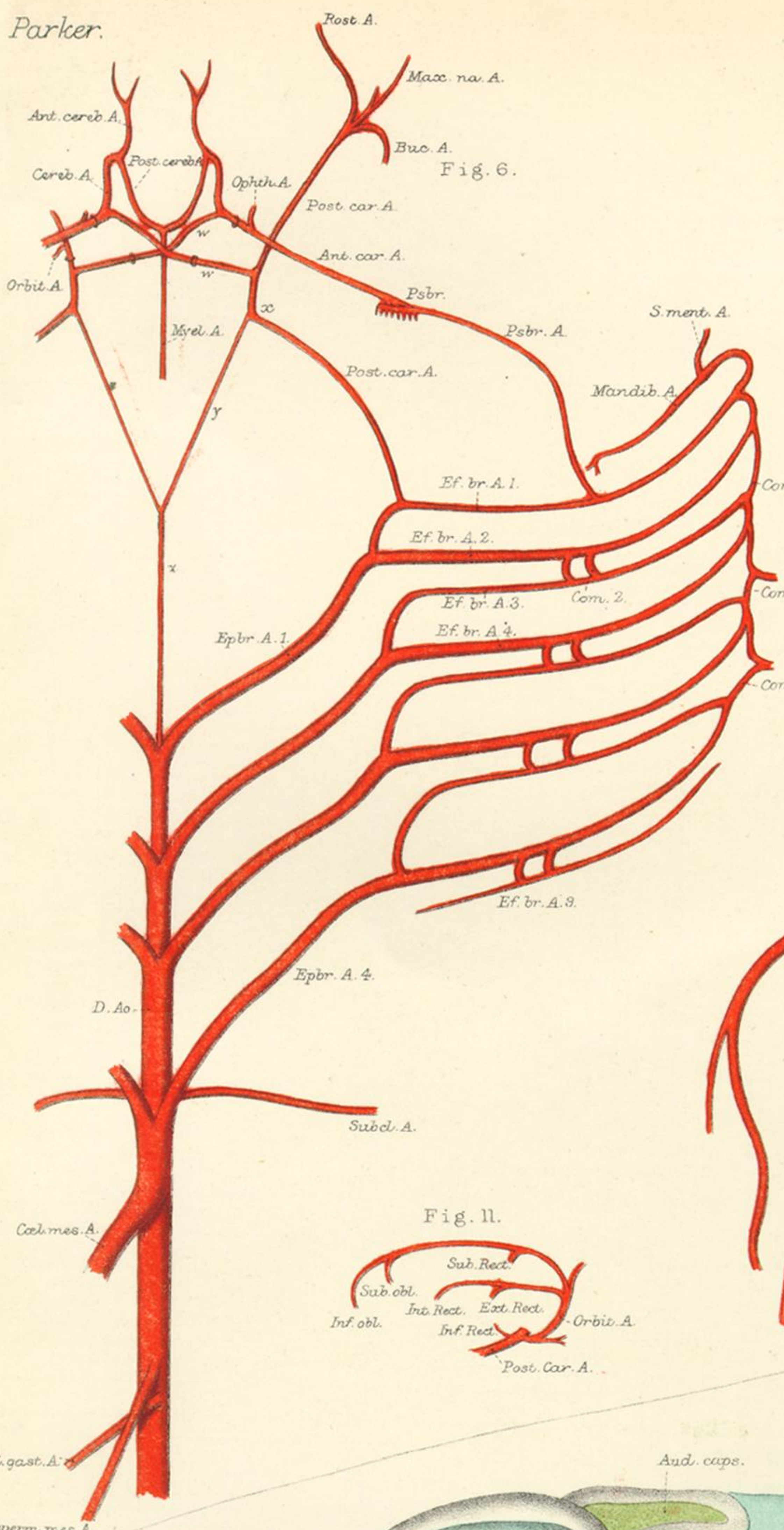


Fig. 7.

Fig. 11.

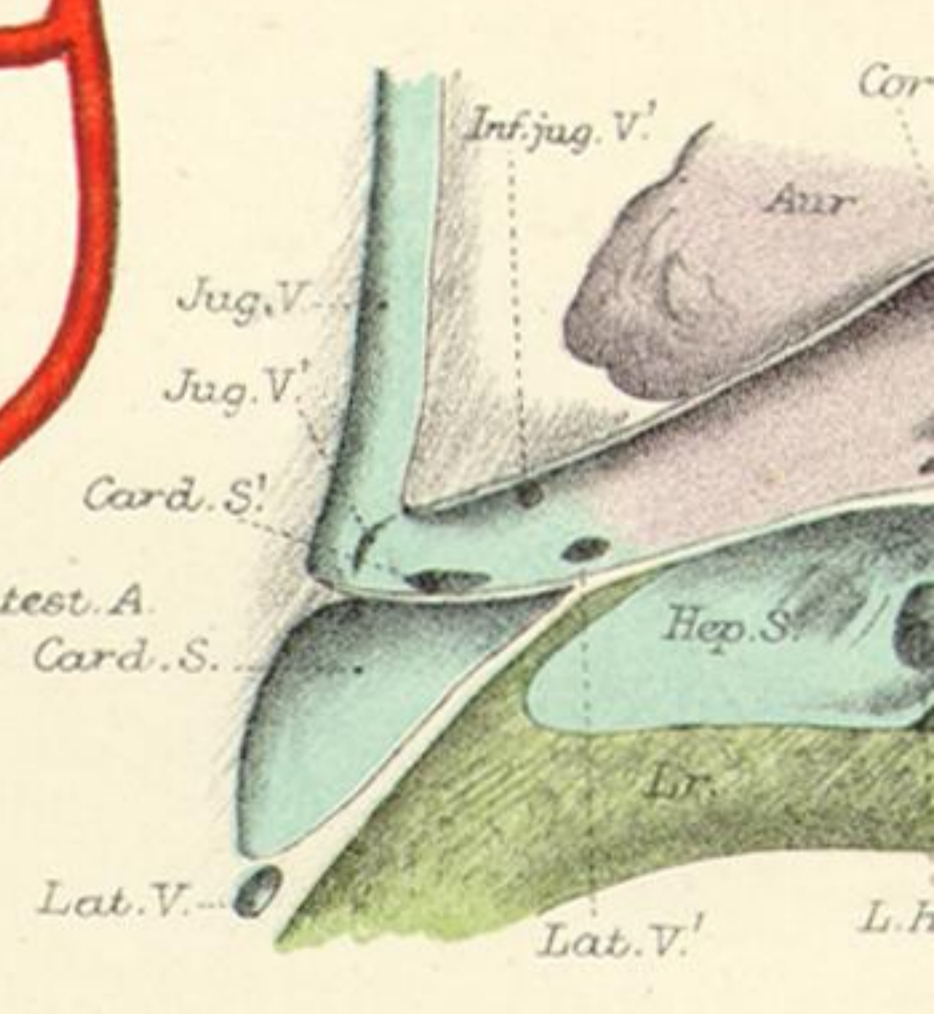
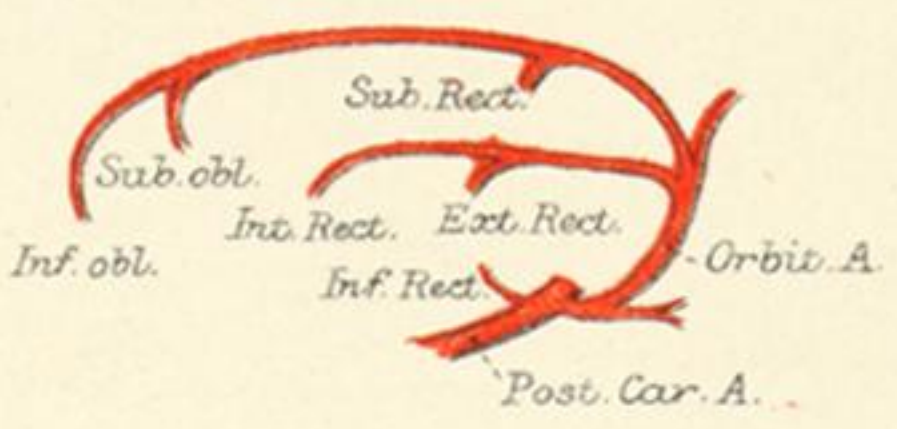
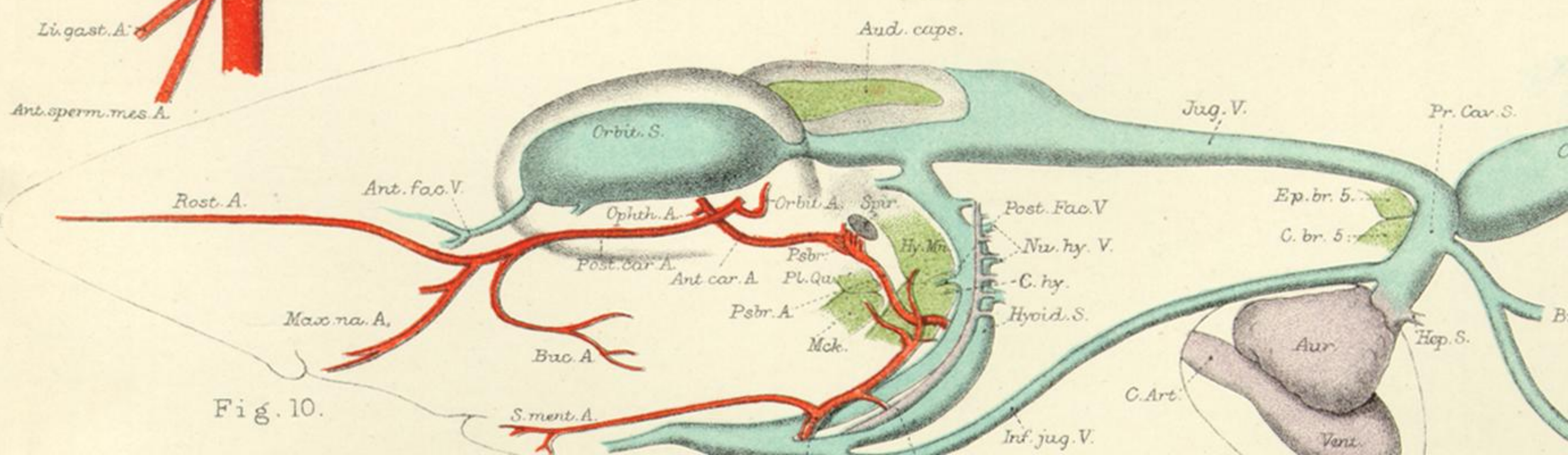


Fig. 10.



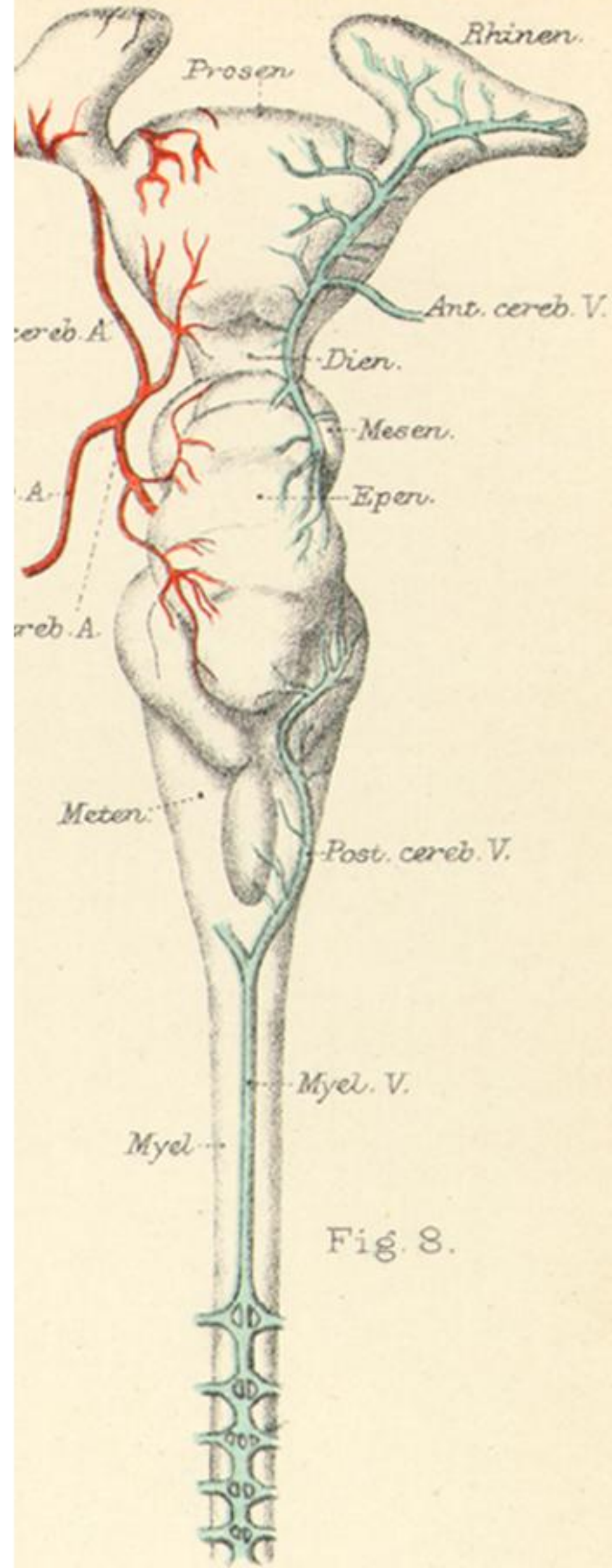


Fig. 8.

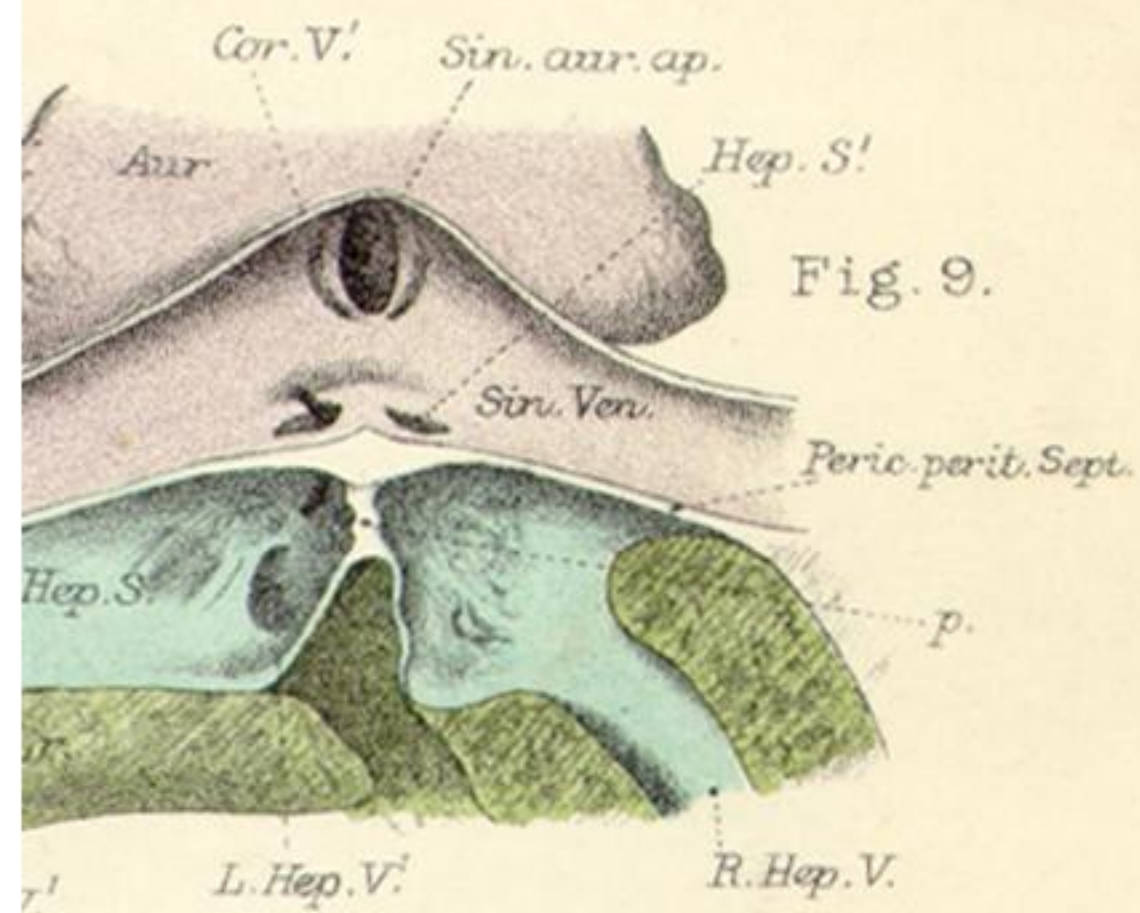


Fig. 9.

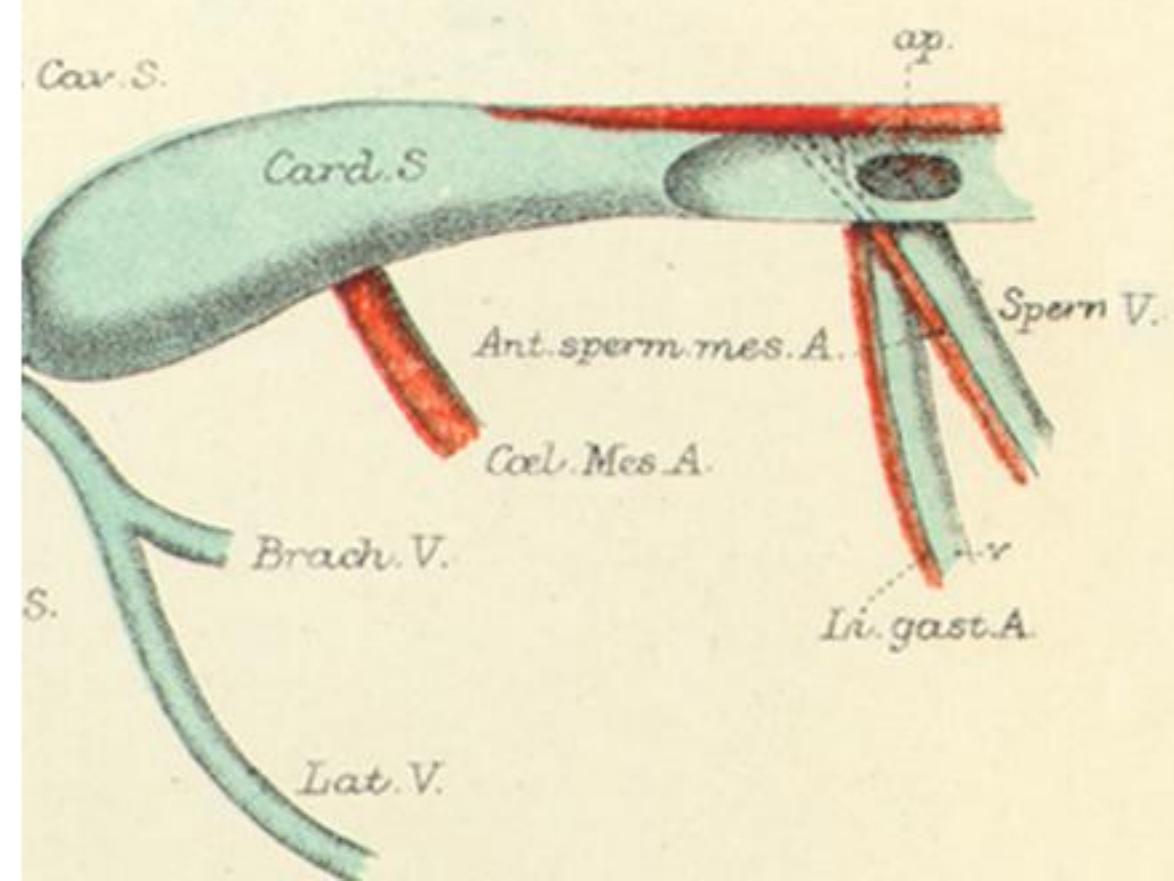
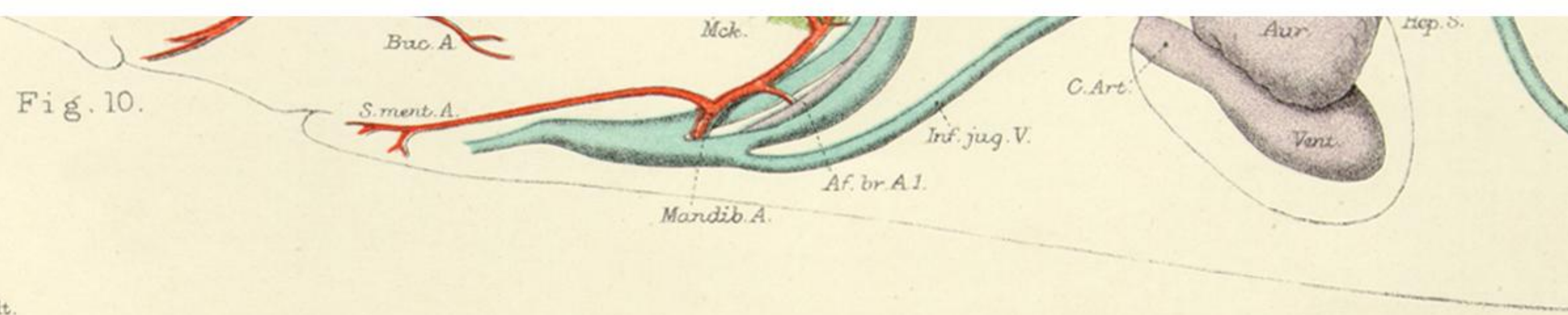
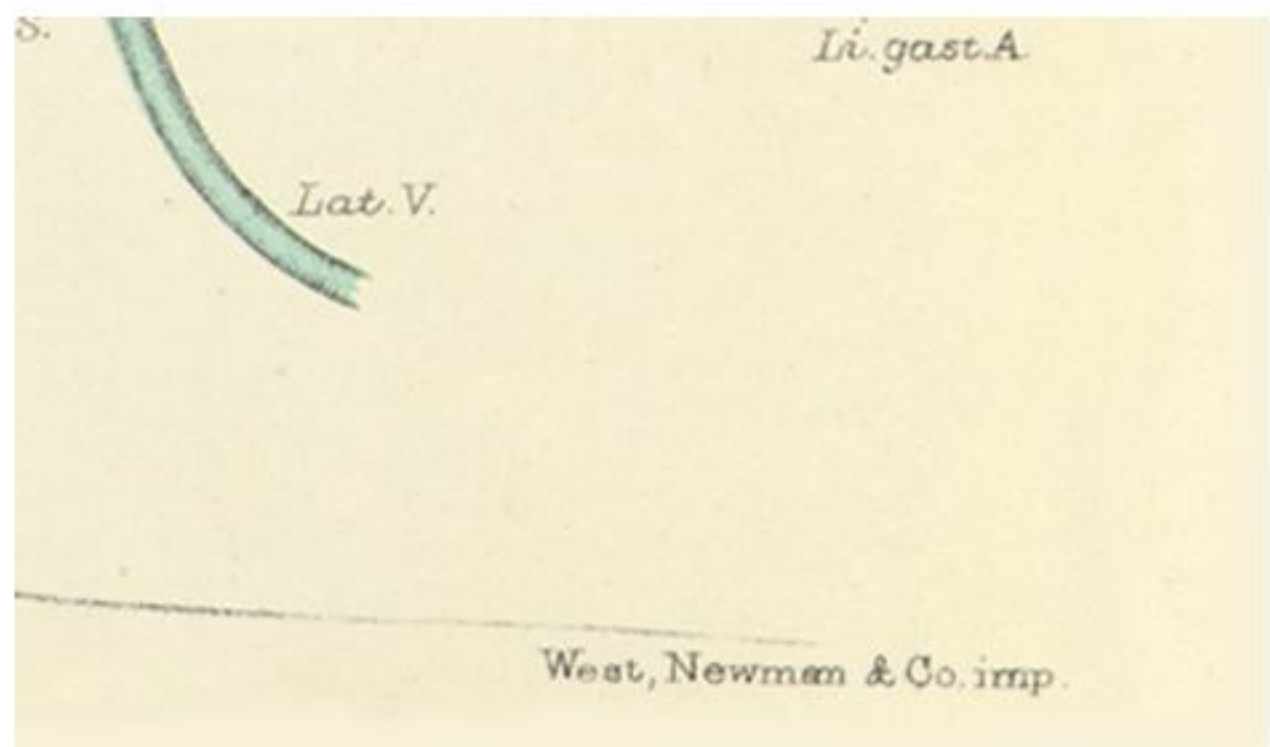


Fig. 10.



T.J.P. ad.nat. del.

Mustelus antarcticus.



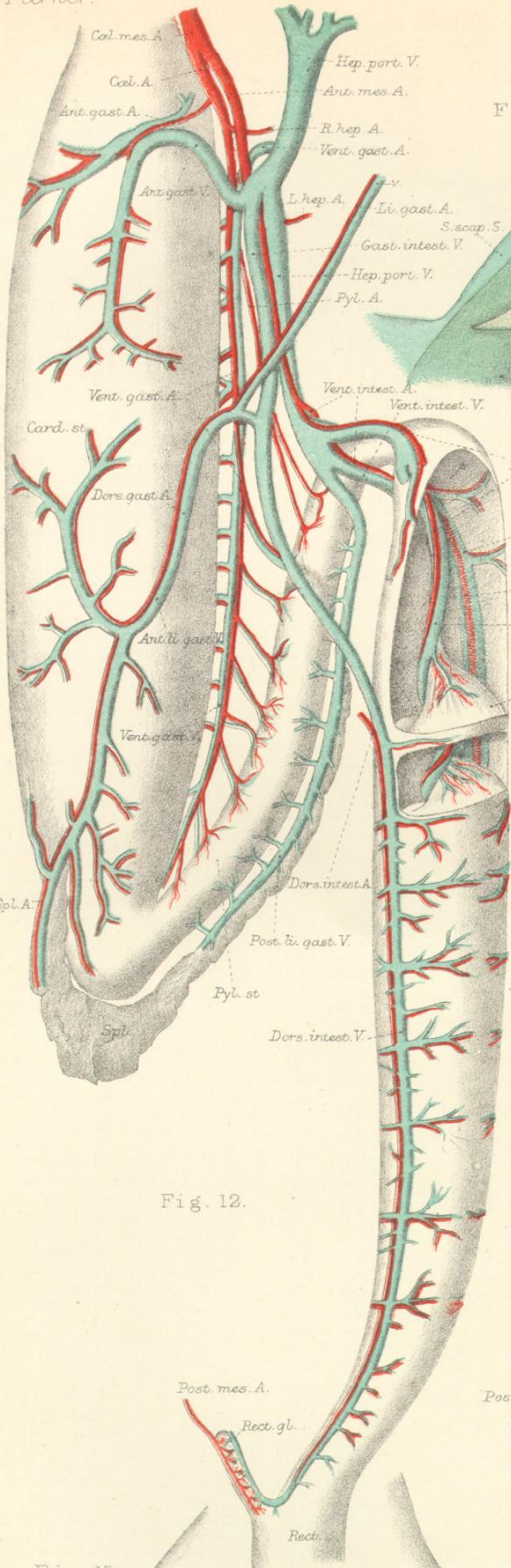


Fig. 12.

Fig. 16.

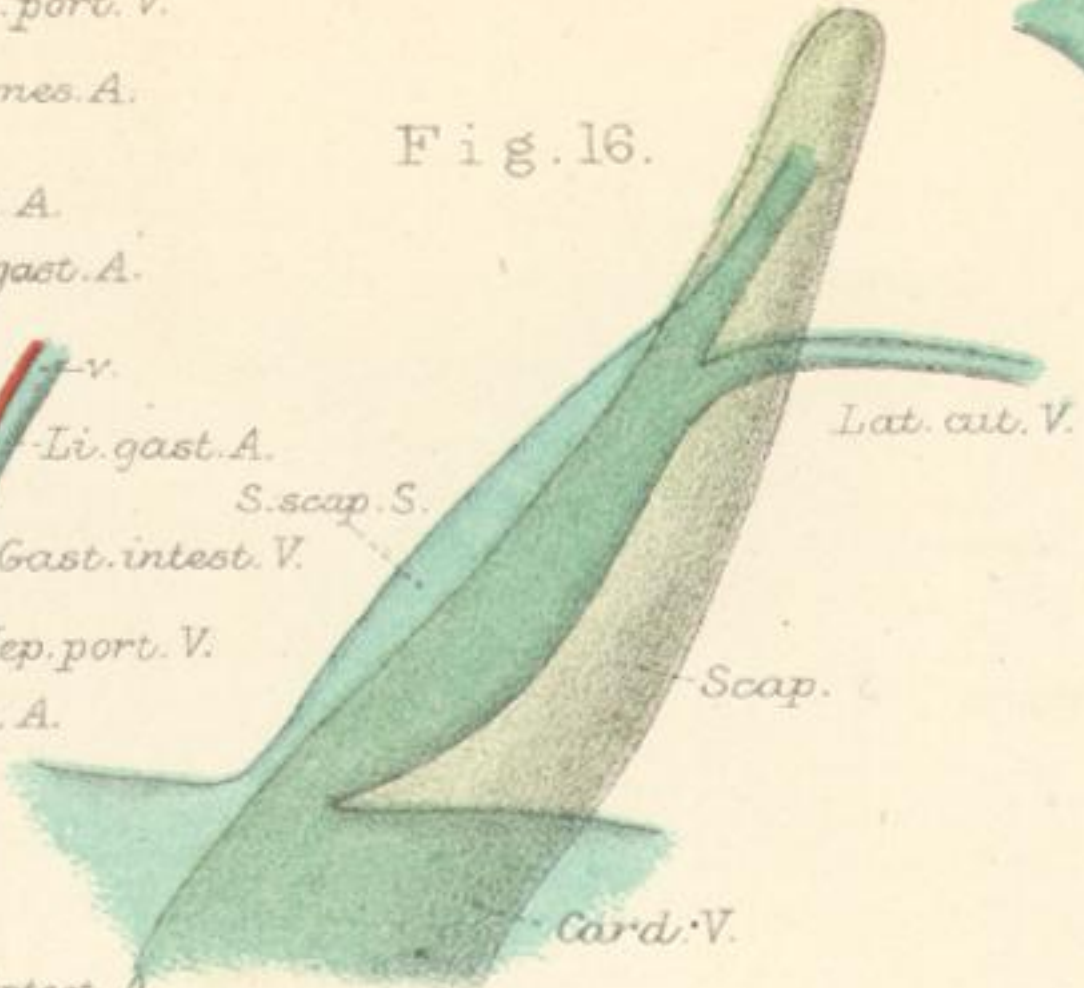


Fig. 13.

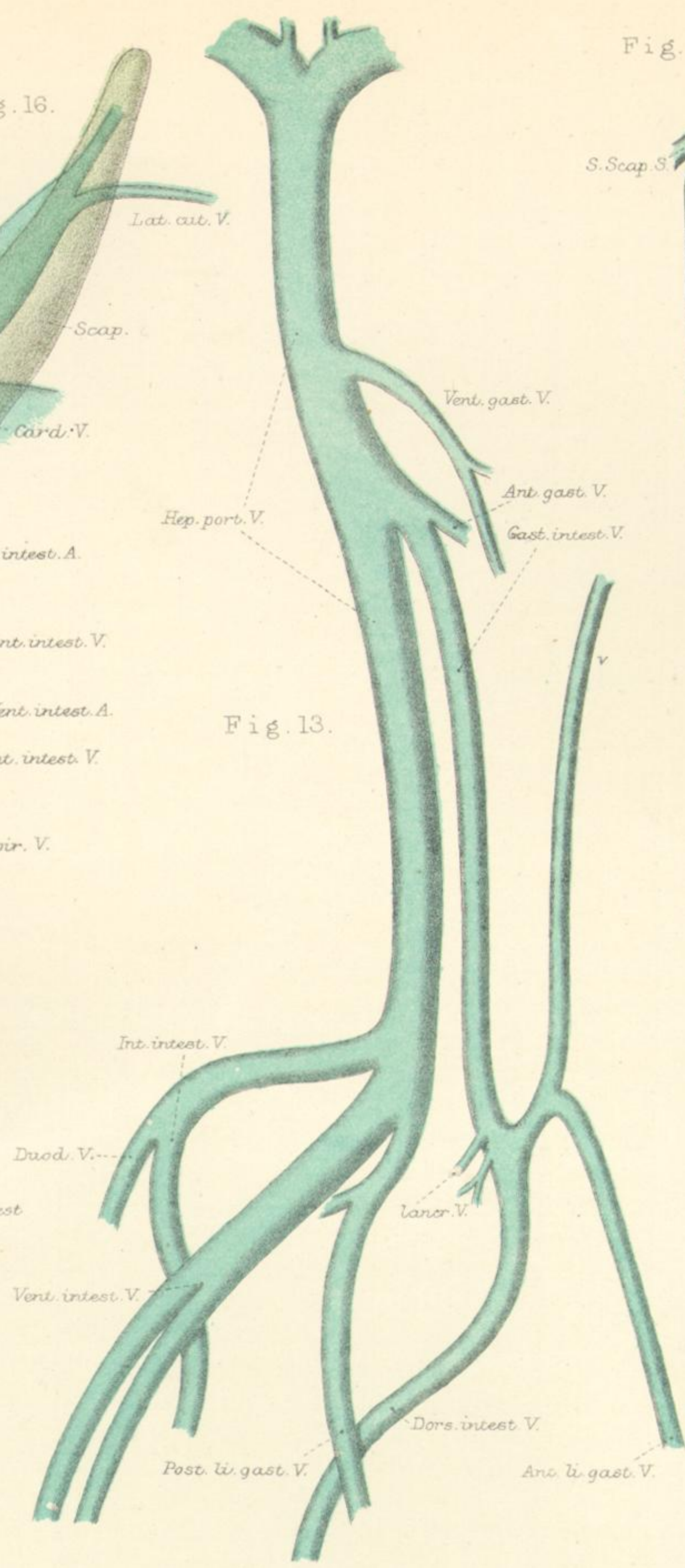
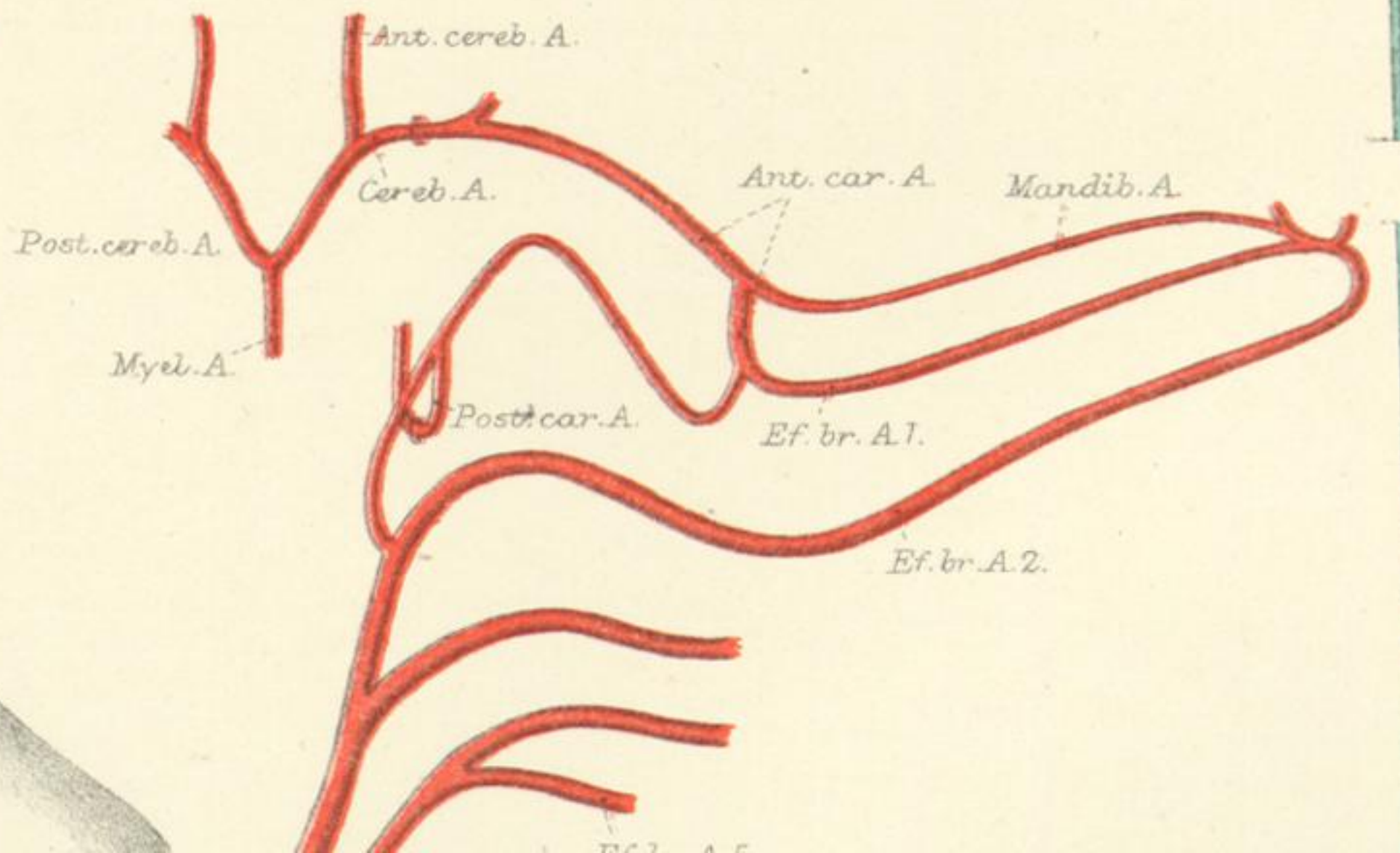


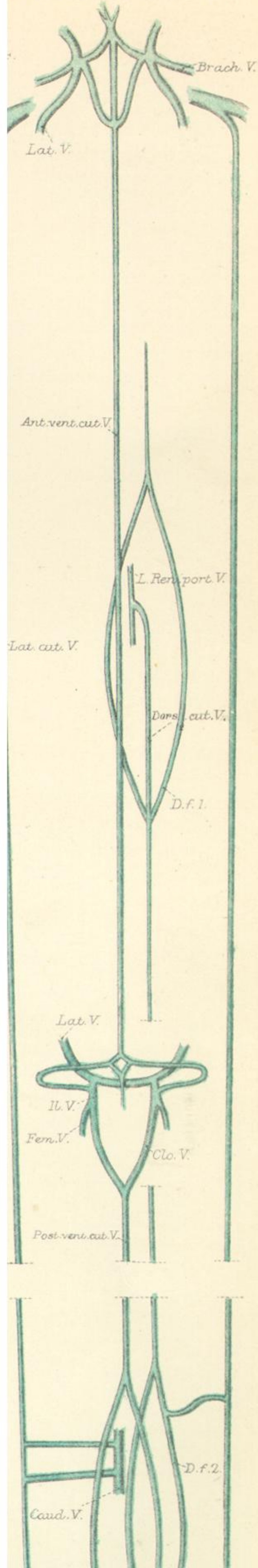
Fig. 14.

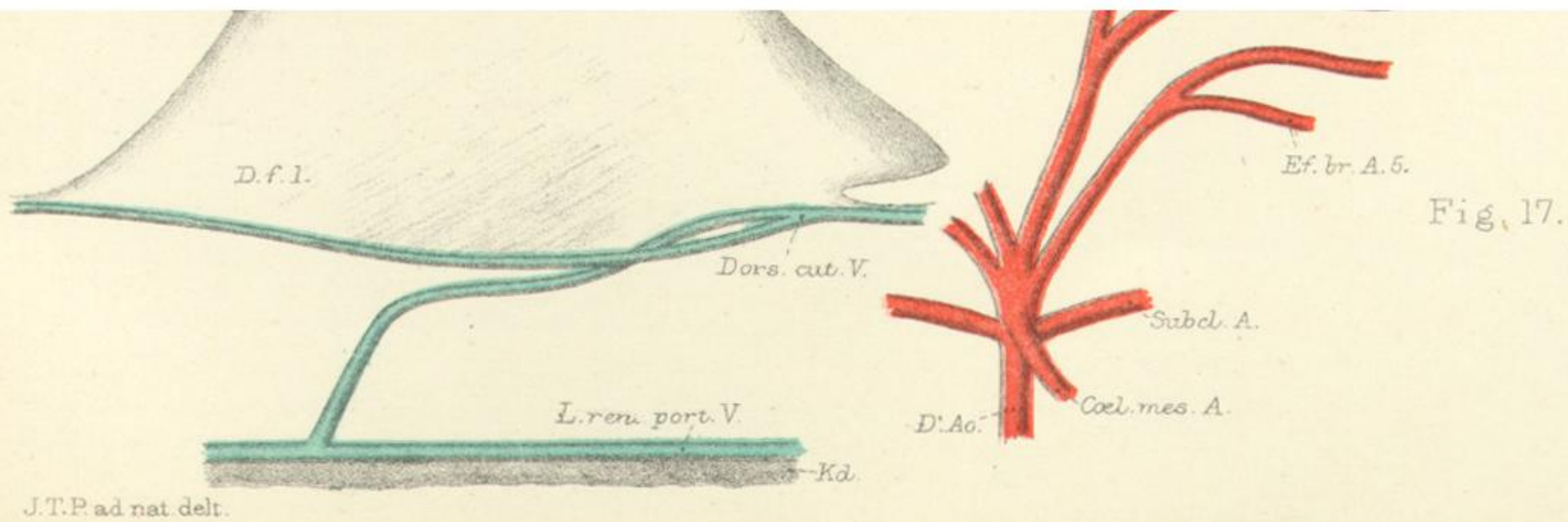
S. Scap. S.
Lat. V.
Ant. vent. cu.
Lat. cut. V.
Lat.
Il. V.
Fem. V.
Post. ven.

Fig. 15.



Caud. V.





Figs. 12: 16, *Mustelus antarcticus*: Fig. 17, *Callorhynchus antarcticus*.

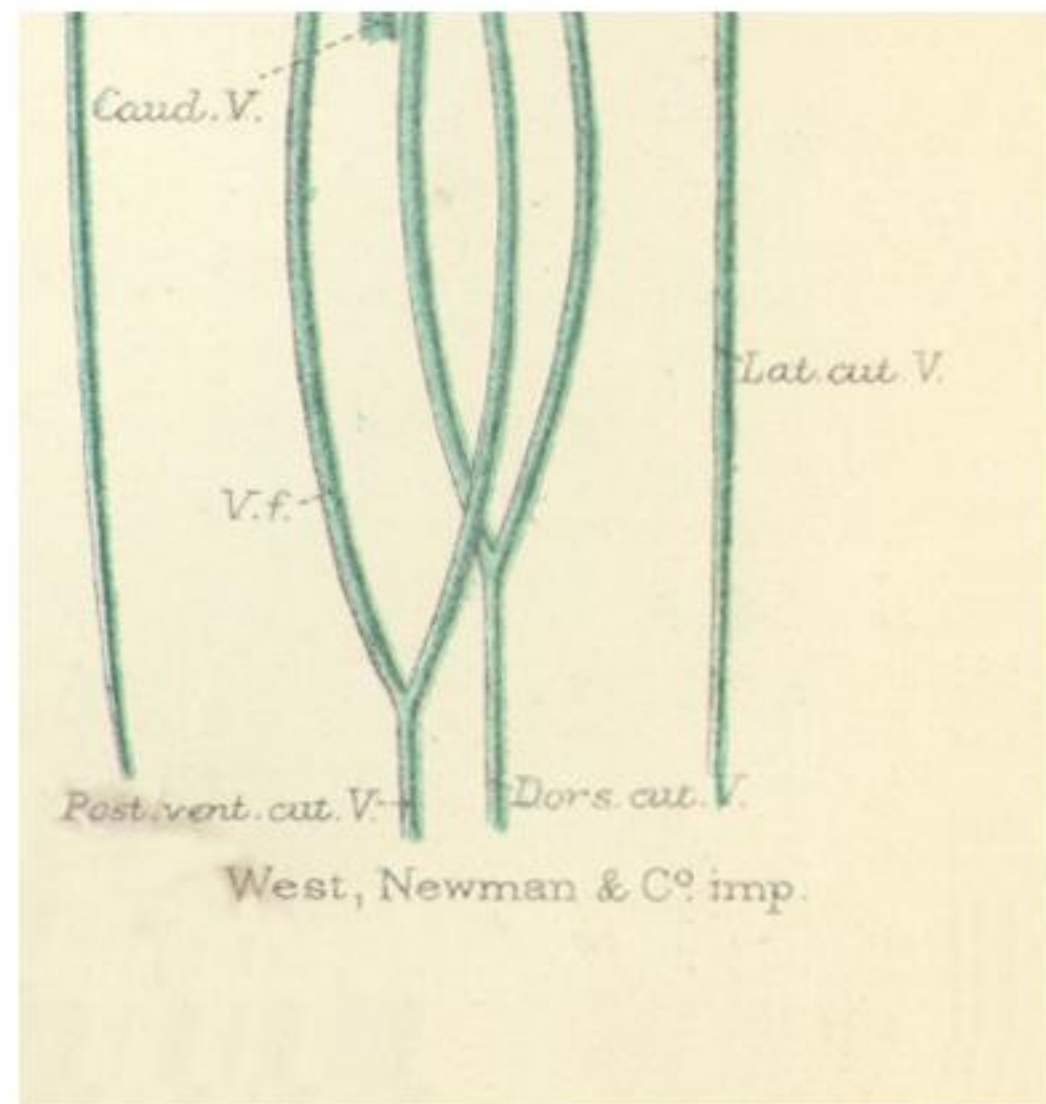


Fig. 18.

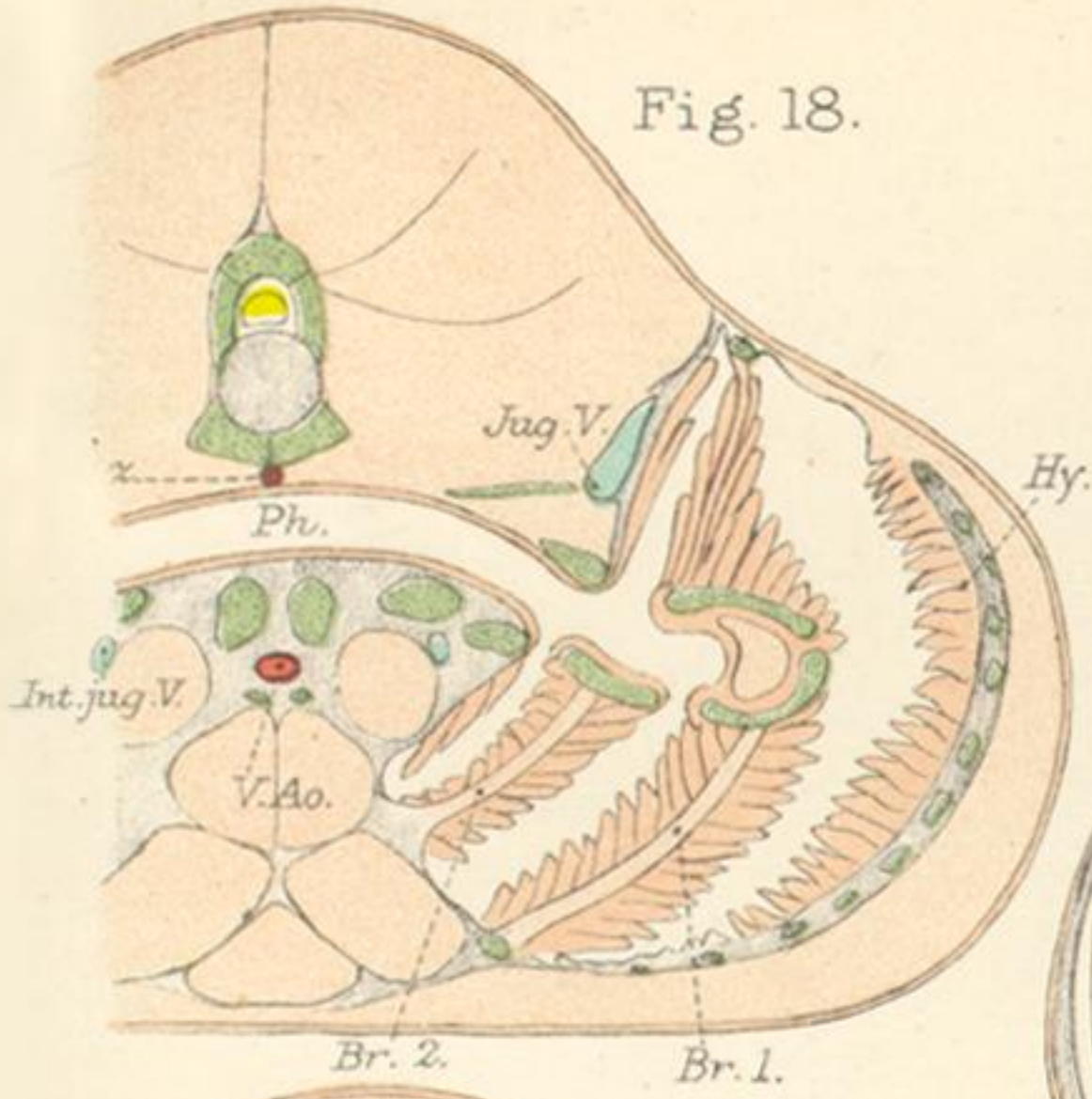


Fig. 19.

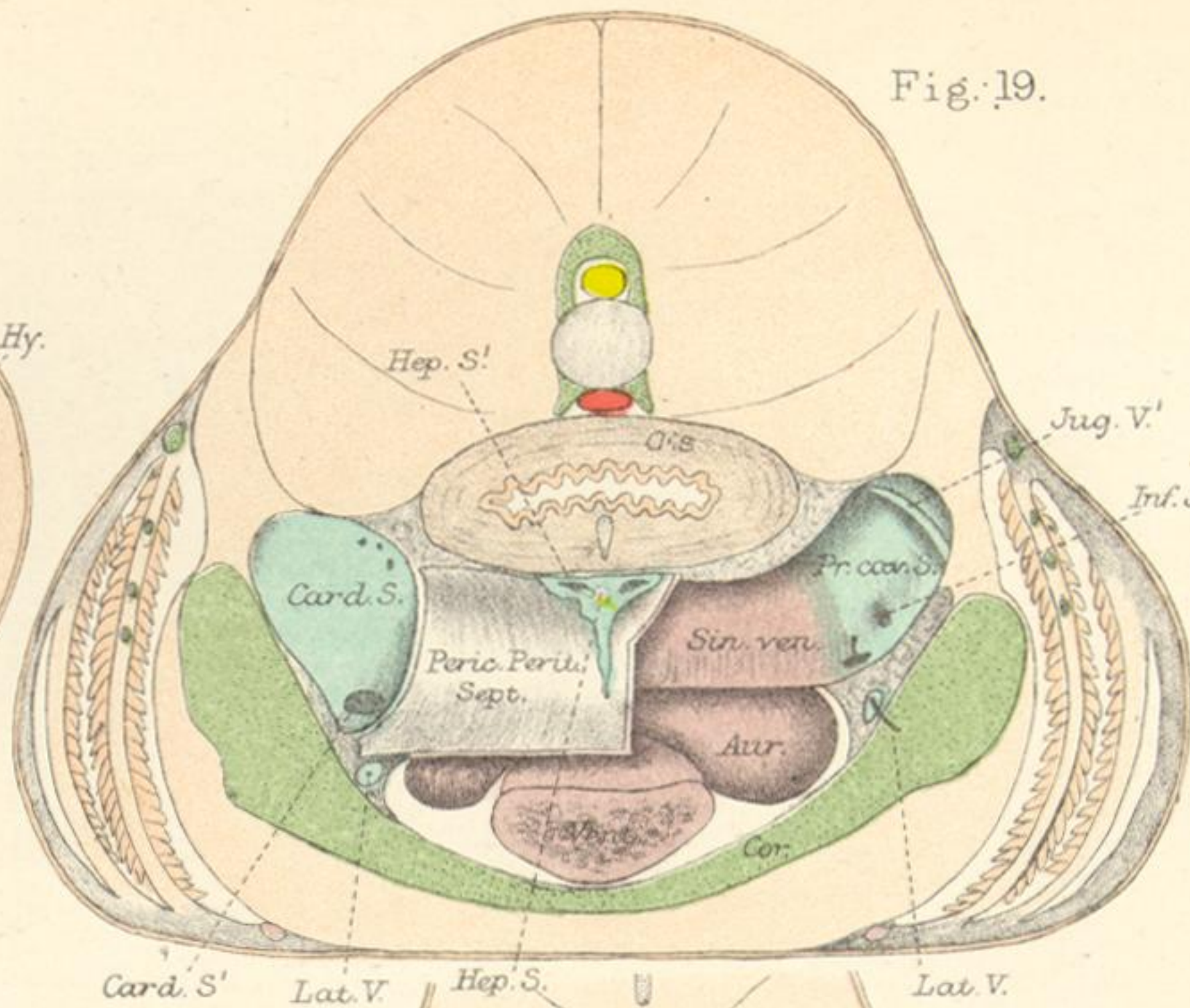


Fig. 20.

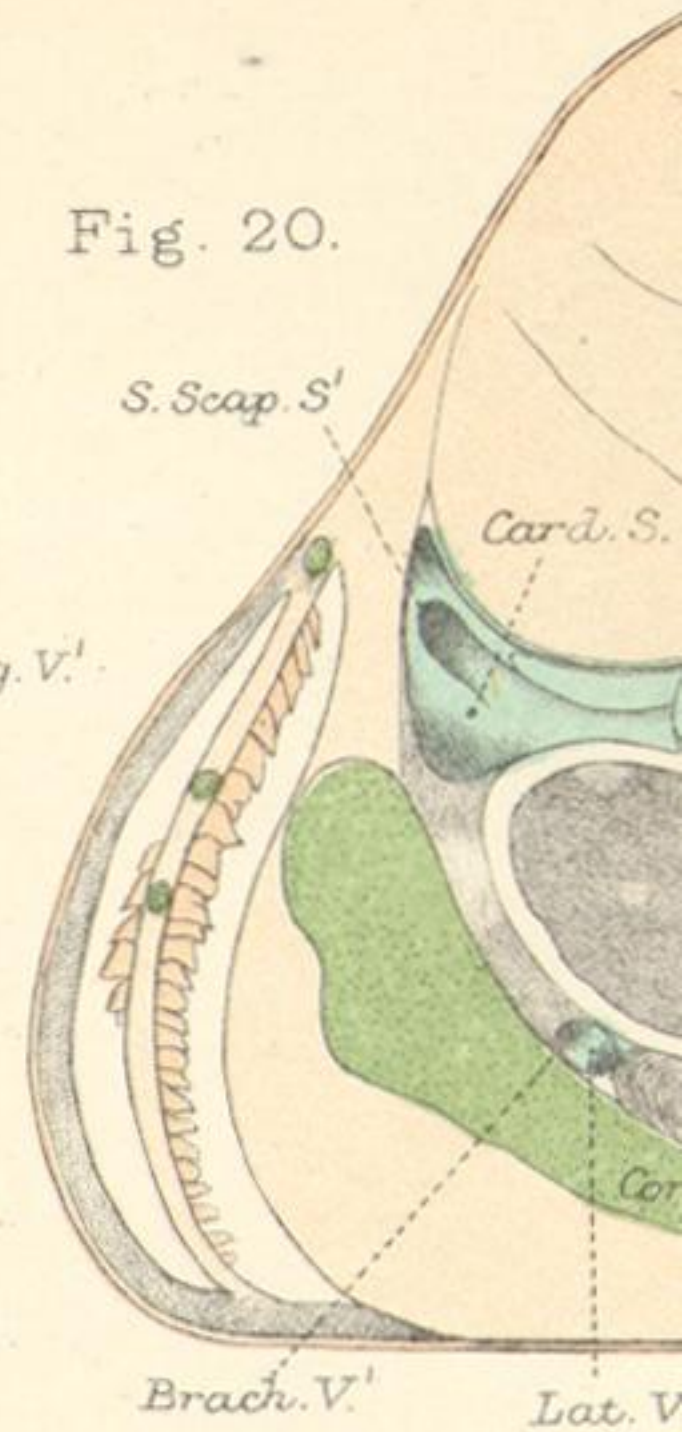


Fig. 21.

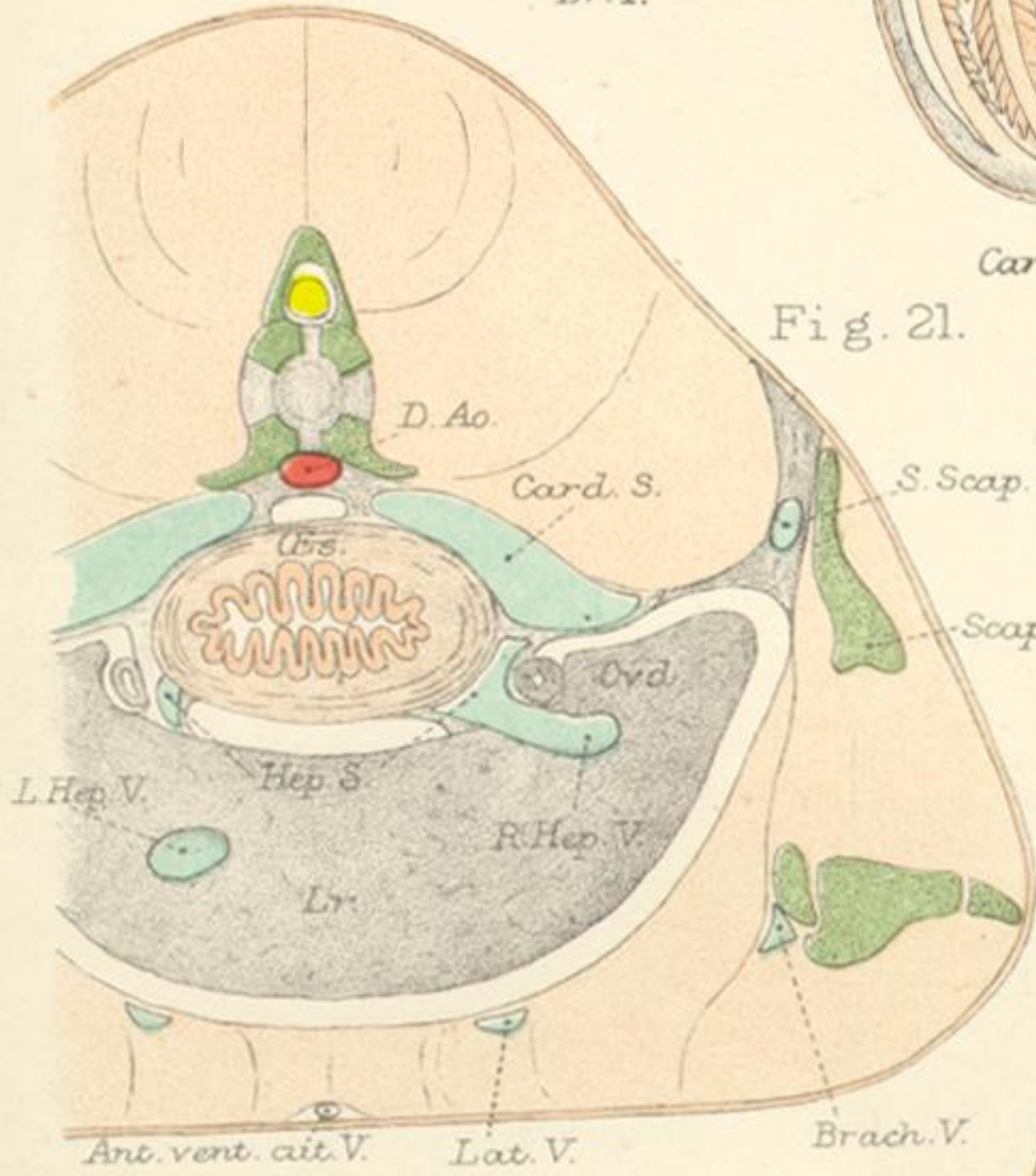


Fig. 22.

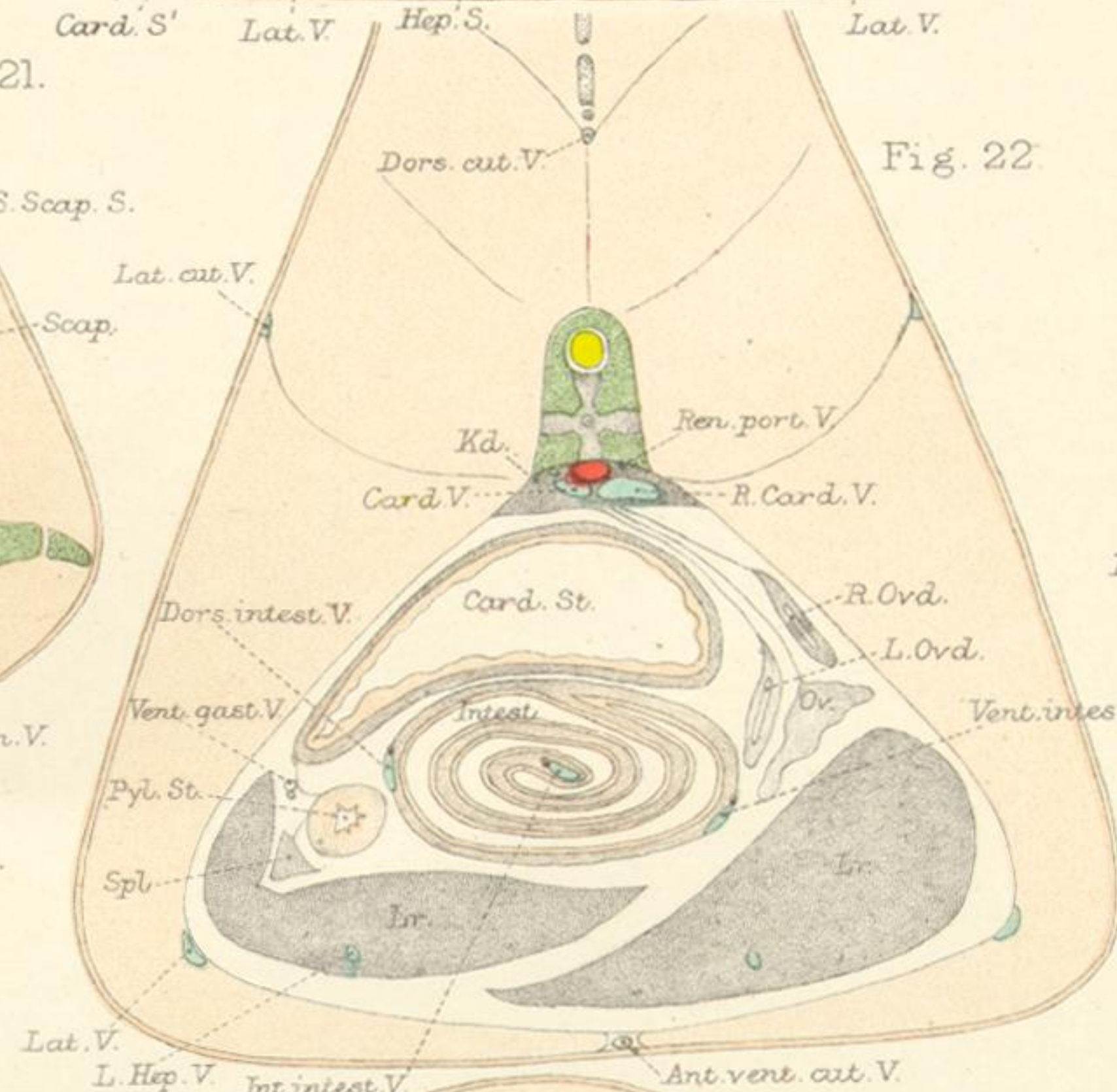


Fig. 24.

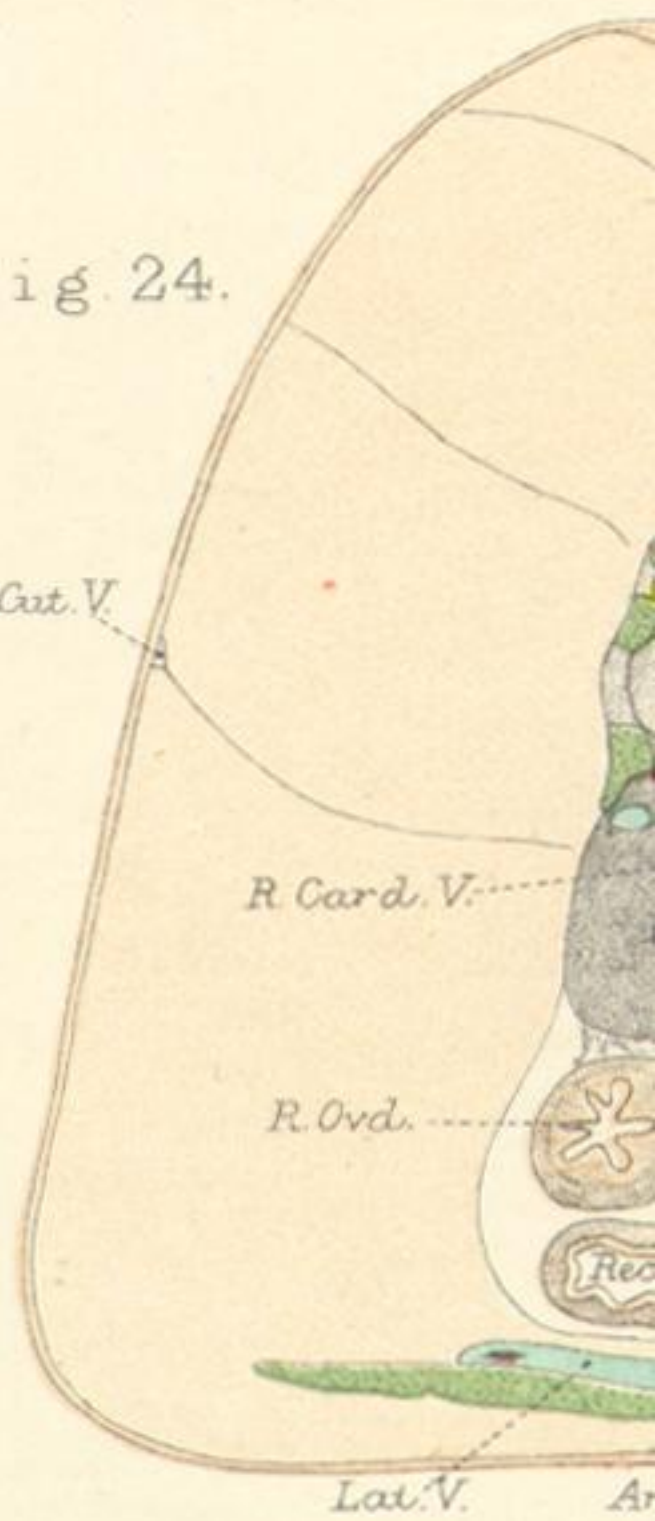


Fig. 23.

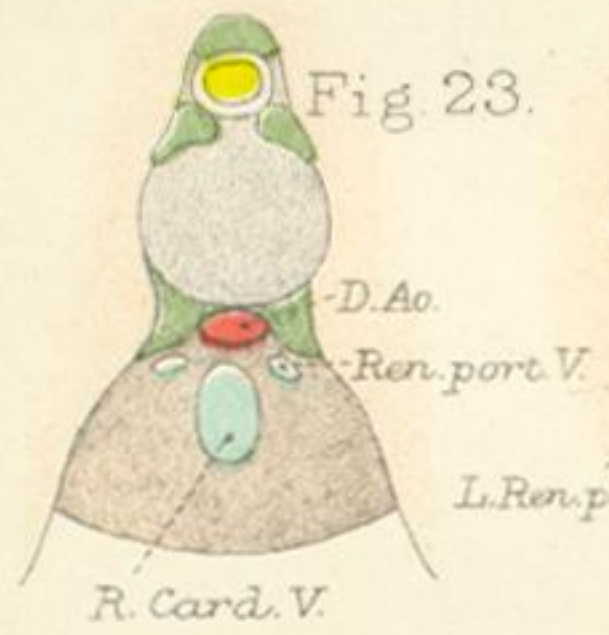


Fig. 25.




Fig. 26.

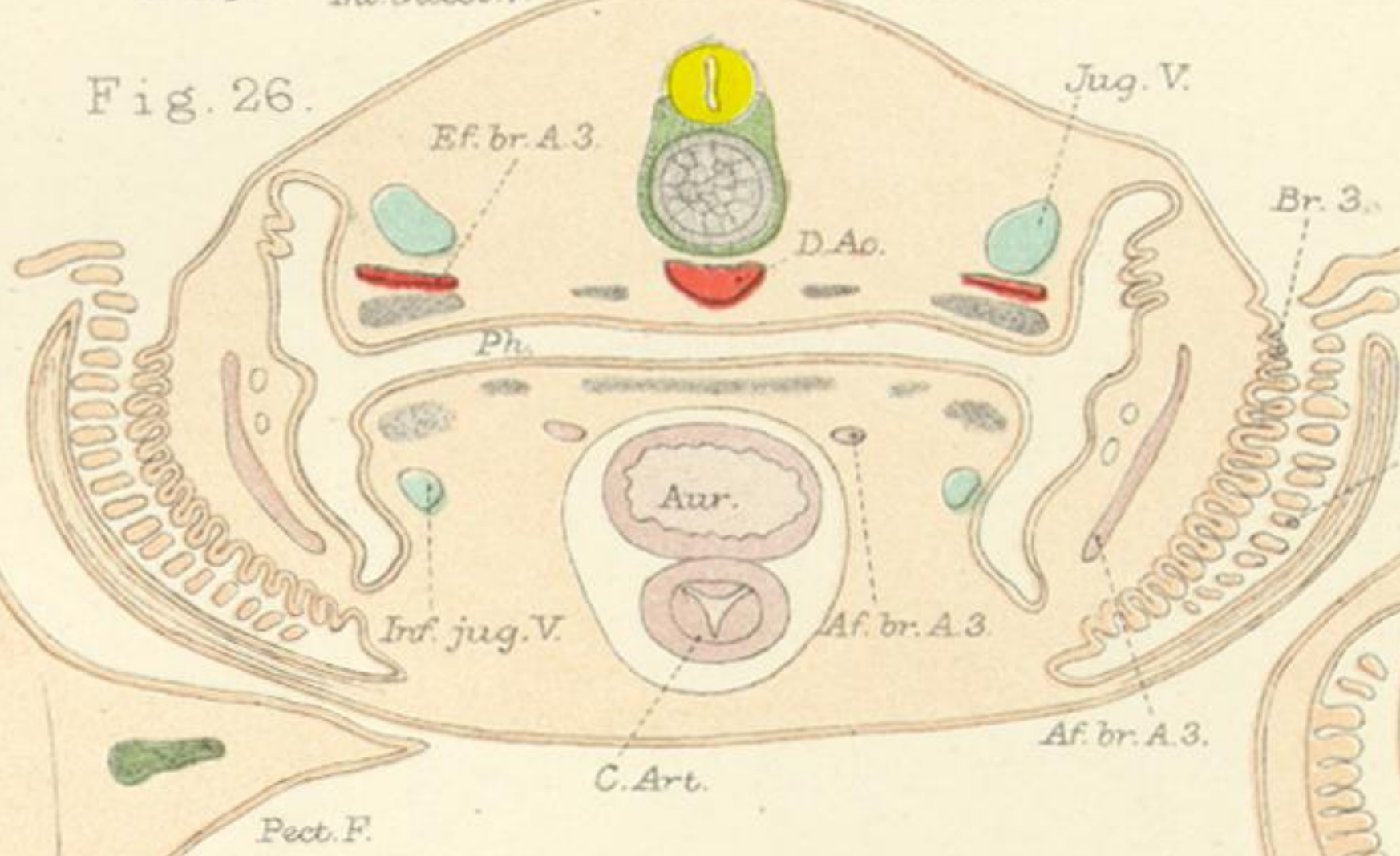


Fig. 27.

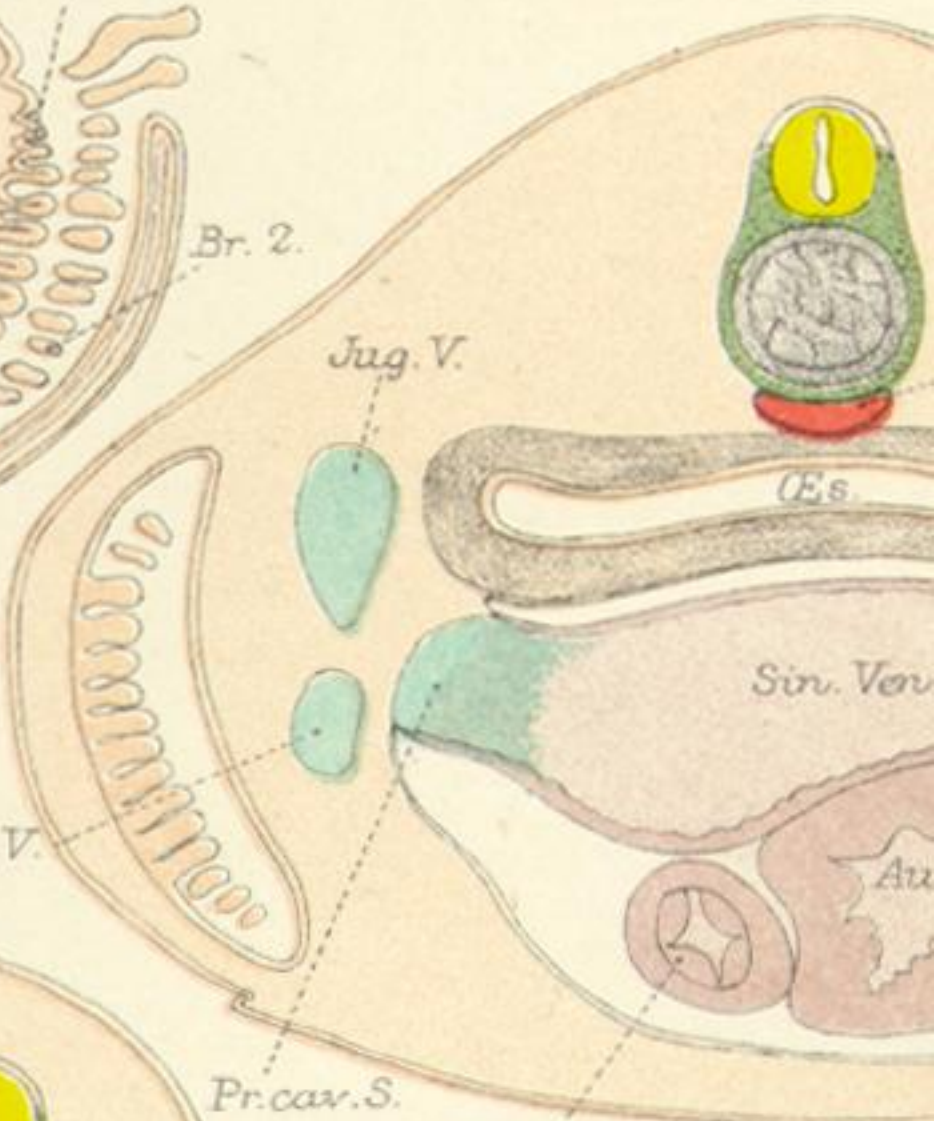


Fig. 29.

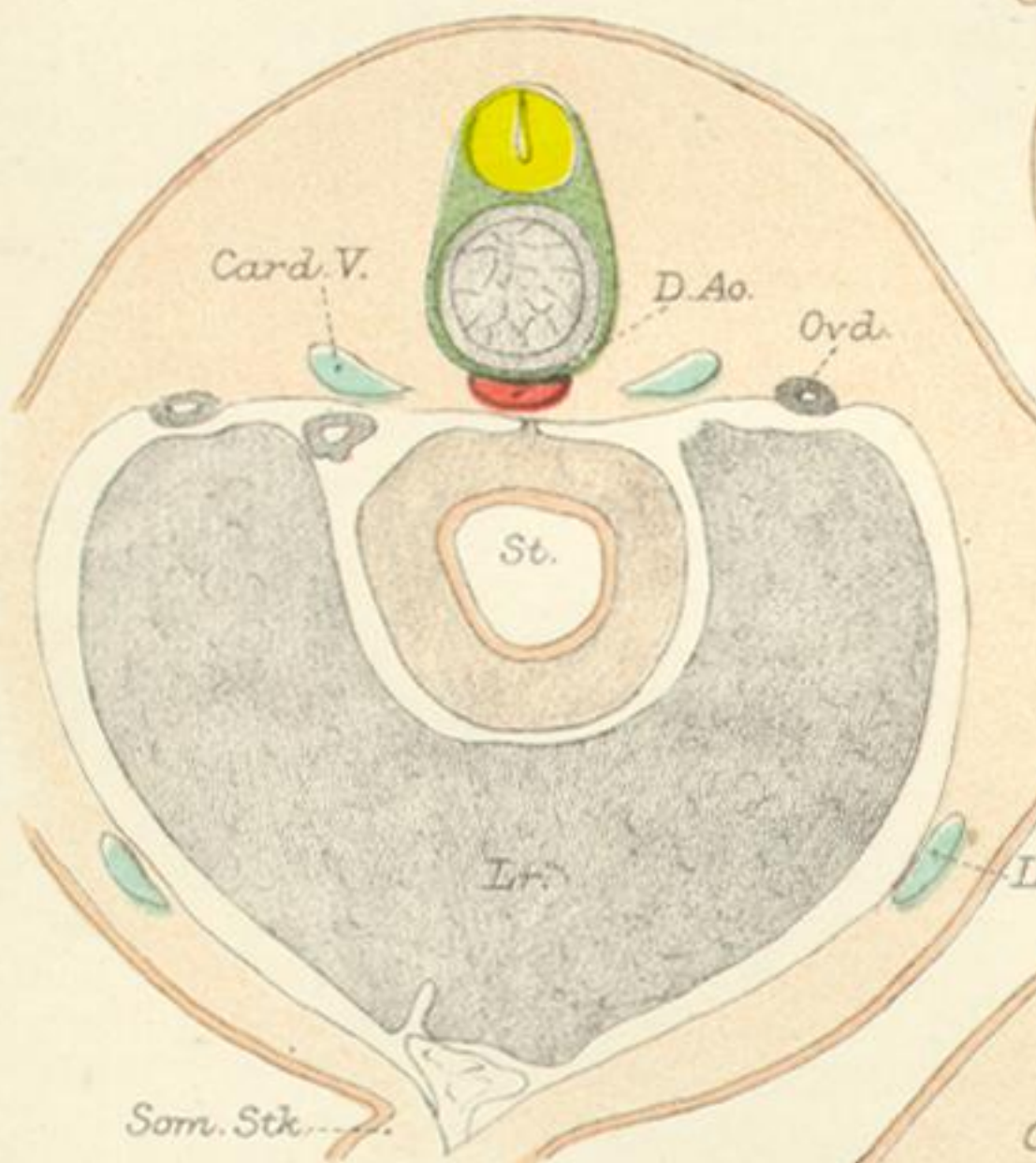


Fig. 28.

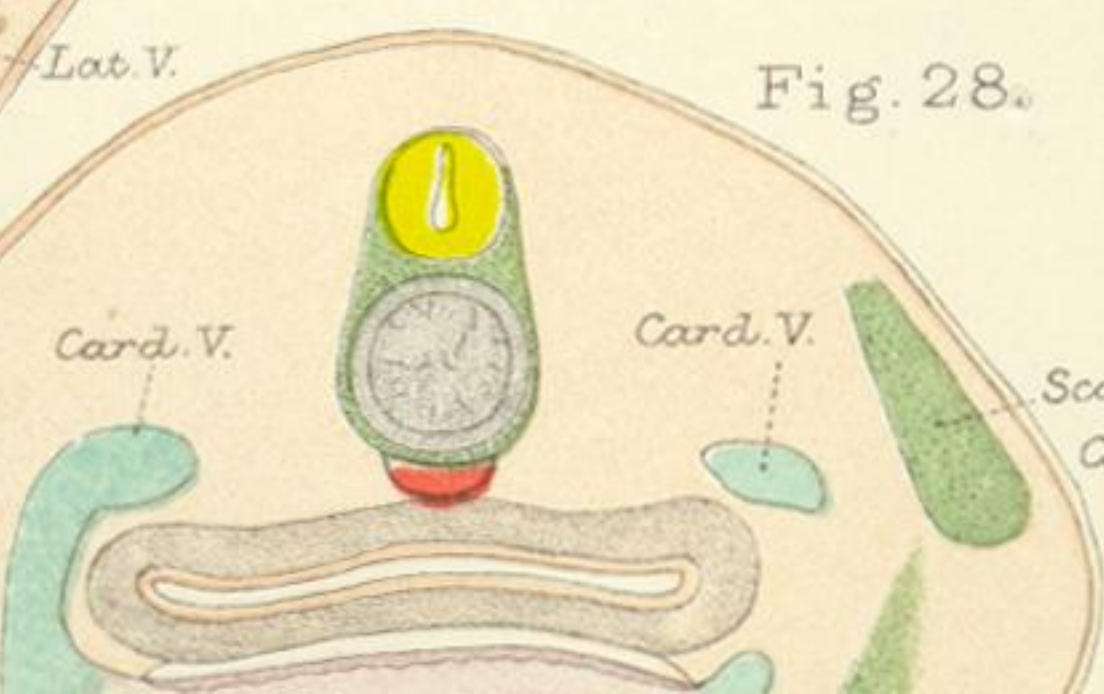


Fig. 30.

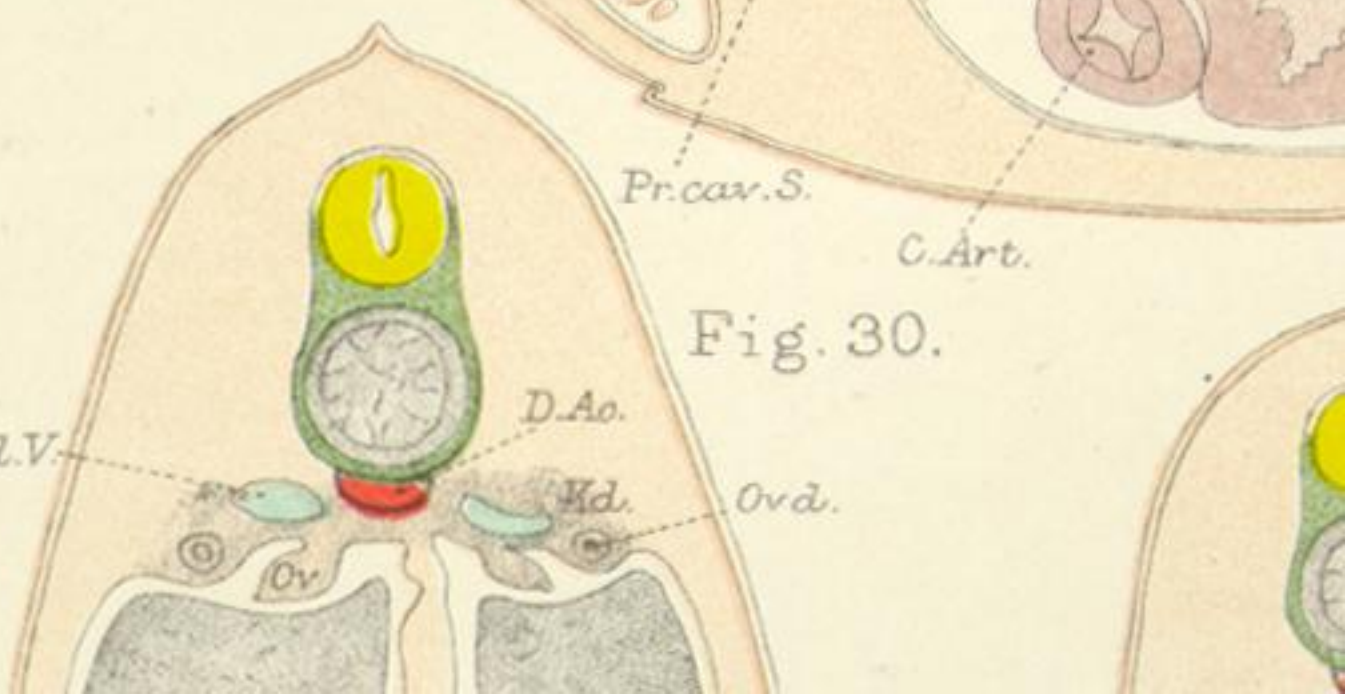
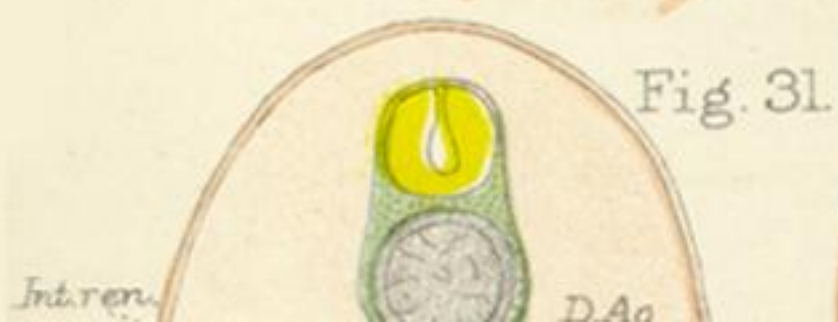

Fig. 31.



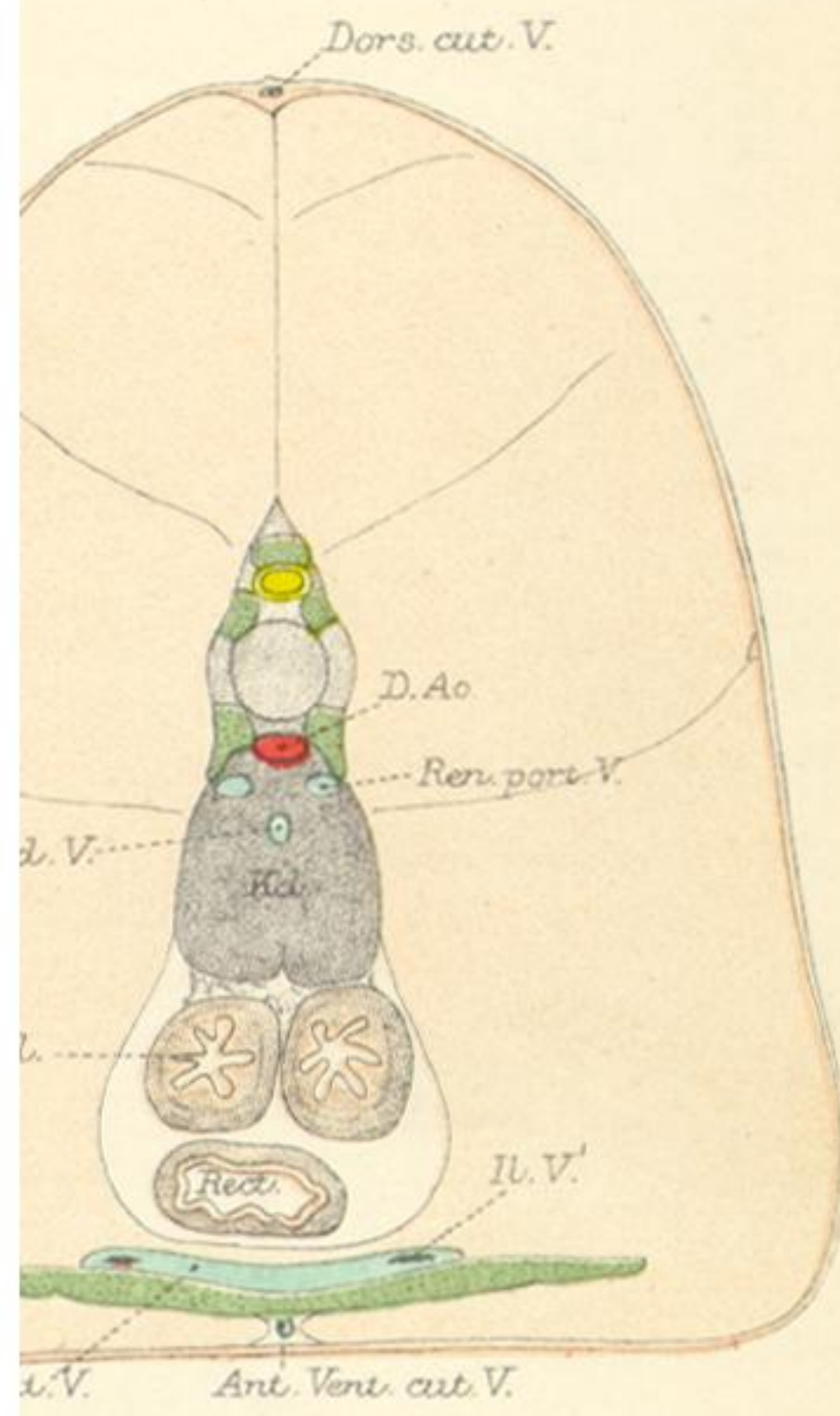
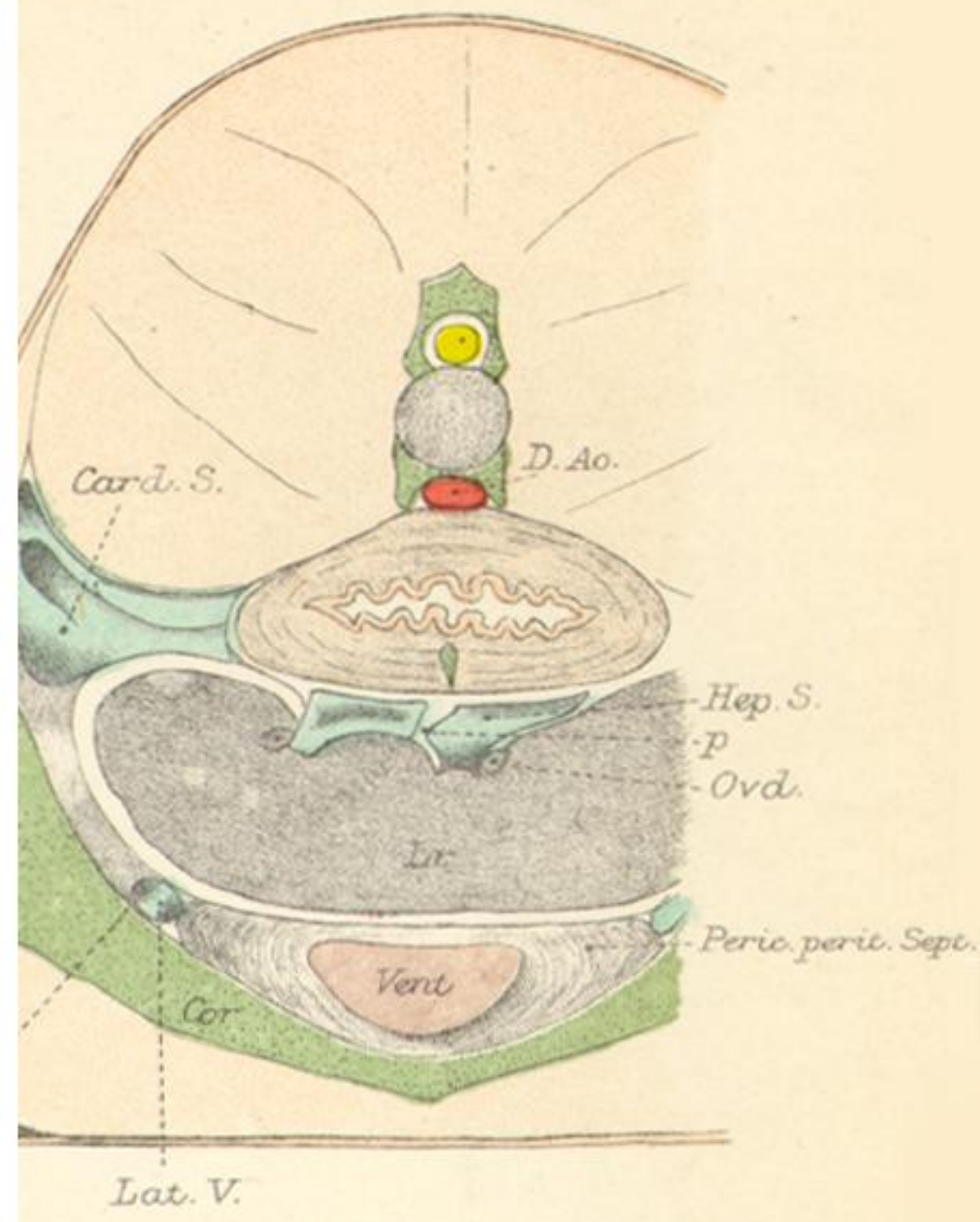


Fig. 27.

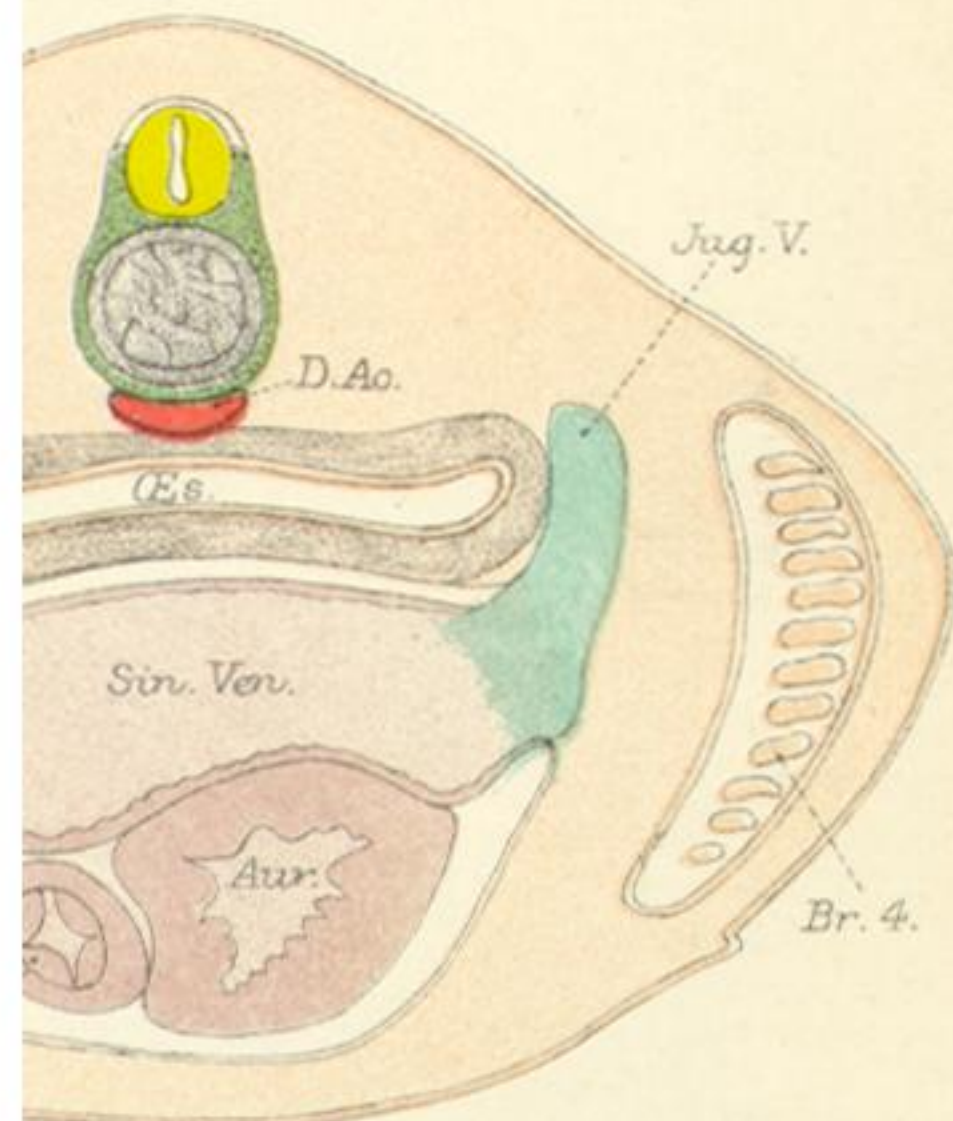
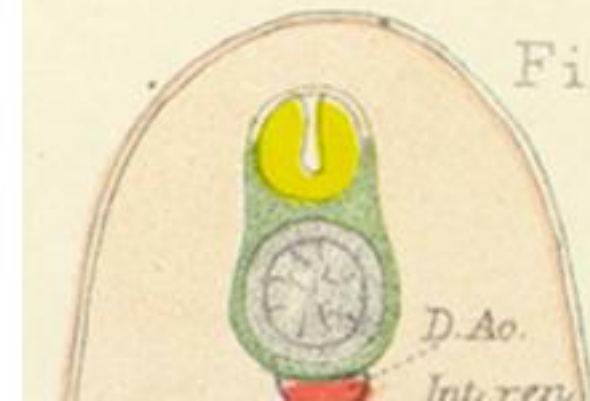
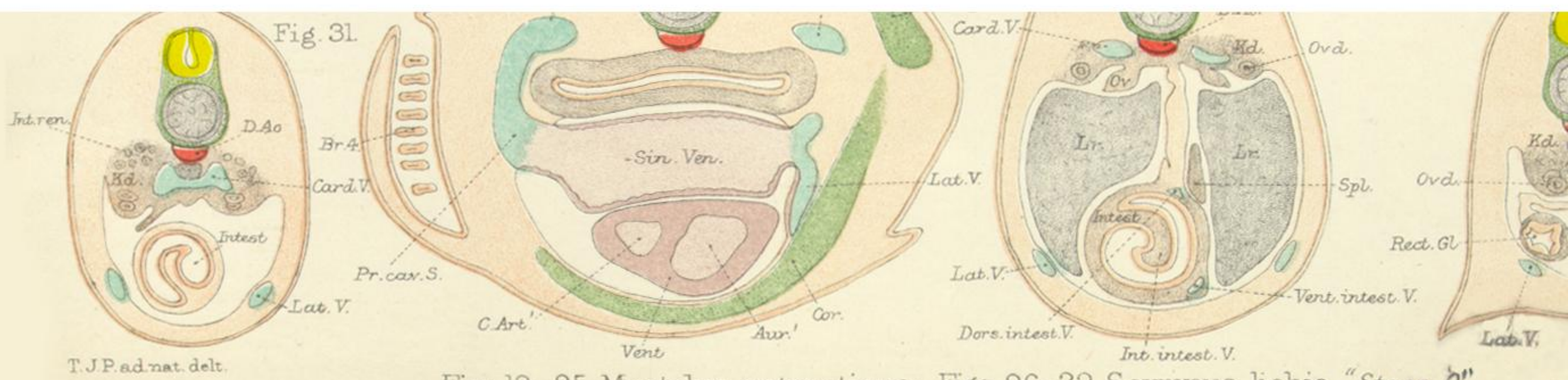


Fig. 32.





T. J. P. ad. nat. del.

Figs. 18-25, *Mustelus antarcticus*: Figs. 26-32, *Scymnus lichia*, "Stage 0"

